ORIGINAL ARTICLE

Laparoscopic Approach for Suspected Early-Stage Gallbladder Carcinoma

Jai Young Cho, MD, PhD; Ho-Seong Han, MD, PhD; Yoo-Seok Yoon, MD, PhD; Keun Soo Ahn, MD; Young-Hoon Kim, MD, PhD; Kyoung-Ho Lee, MD, PhD

Objective: To determine the feasibility of the laparoscopic approach for treating suspected early-stage gallbladder carcinoma.

Design, Setting, and Patients: Prospective study from a university hospital. From May 10, 2004, to October 9, 2007, the laparoscopic approach was considered for treating 36 patients with suspected gallbladder carcinoma at T2 or less without liver invasion based on the preoperative computed tomographic scan. To further exclude liver invasion, preoperative endoscopic ultrasonography (US) and laparoscopic US were additionally performed. Frozen biopsy was performed after completing the cholecystectomy. If carcinoma was found, laparoscopic lymphadenectomy was performed.

Main Outcome Measures: Feasibility and operative outcome.

Results: Three patients who had liver invasion on endoscopic US underwent open surgery. An additional 3 patients who had liver invasion noted on laparoscopic US had their surgical procedure converted to laparotomy. Finally, 30 patients underwent a laparoscopic procedure. With combined computed tomography, endoscopic US, and laparoscopic US, the negative predictive value for excluding hepatic invasion reached 100%. For the 12 patients who had benign lesions noted on their frozen biopsies, their laparoscopic surgical procedure was completed. The remaining 18 patients who had gallbladder carcinoma underwent additional laparoscopic lymphadenectomy. During laparoscopic lymphadenectomy 1 conversion occurred owing to bleeding, the median operative time was 190 minutes, and the median blood loss was 50 mL. The complication rate was 16.7% and the median postoperative hospital stay was 4 days. After a median follow-up of 27 months, all 18 patients who underwent laparoscopic lymphadenectomy survived without any evidence of recurrence or metastasis.

Conclusion: Laparoscopic treatment is feasible and safe in selected patients with early-stage gallbladder carcinoma.

Arch Surg. 2010;145(2):128-133

Although many authors have reported improved survival rates for patients with gallbladder carcinoma (GBC) after radical surgery,[1,2] the optimal surgical approach may vary according to the disease stage at the time of diagnosis. For patients with pT1 GBC, performing simple cholecystectomy alone can be a curative surgical procedure.[3,4] The pT2 GBC, in which the tumor is confined within the subserosal layer of the gallbladder wall, may be accompanied by nodal involvement.[5-7] Therefore, additional locoregional lymph node dissection is recommended for GBC that equals or exceeds pT2. In general, if GBC is preoperatively suspected, open surgery is recommended for performing radical cholecystectomy; however, some of these patients and especially those with polypoid lesions of the gallbladder are sometimes postoperatively confirmed to have a benign lesion.[8]

See Invited Critique at end of article

With the wide use of laparoscopy for cholecystectomies, the likelihood of incidentally discovering GBC during or after laparoscopic cholecystectomy (LC) has also increased.[9] If GBC is incidentally discovered during LC, open conversion is generally recommended. Further, when GBC is detected postoperatively in patients who have undergone simple cholecystectomy under the suspicion of benign disease, a second operation for radical re-resection is recommended for those patients with pT2 GBC or greater.

Laparoscopic cholecystectomy can now be safely performed for cholecystolithiasis

Author Affiliations: Departments of Surgery (Drs Cho, Han, Yoon, and Ahn) and Radiology (Drs Kim and Lee), Seoul National University Bundang Hospital, Seoul National University College of Medicine, Seoul, Korea.

©2010 American Medical Association. All rights reserved.
Downloaded From: http://archsurg.jamanetwork.com/ on 04/30/2017

because of the technical improvements and advances in instrumentation. It was previously suggested that LC can be an alternative treatment for early-stage GBC with intramural invasion up to the muscular layer.[10] If primary GBC can be radically resected and the locoregionally involved lymph nodes can be adequately dissected under laparoscopy, the laparoscopic approach could be an alternative treatment for selected patients with early-stage GBC without liver invasion in terms of the oncologic aspects and minimal invasiveness. In addition, if suspected GBC can be ruled out intraoperatively during LC by a frozen biopsy, patients can benefit from the minimal invasiveness of laparoscopy by avoiding otherwise unnecessary open surgery.

Given these facts, we used an intention-to-treat analysis to prospectively evaluate the feasibility and interim outcome of performing laparoscopic approaches in highly selected patients who have preoperatively suspected early-stage GBC.

METHODS

INCLUSION CRITERIA AND ALGORITHM FOR LAPAROSCOPIC APPROACH

The inclusion criteria for the laparoscopic approach were having what was suspected to be an early-stage GBC (radiological T1 or T2 GBC, no liver invasion, and no involvement of the extrahepatic bile duct) on the preoperative computed tomographic (CT) scan. Each patient provided informed consent for the laparoscopic procedures prior to surgery, and approval for this prospective study was obtained from the institutional review board at our hospital.

The treatment algorithm for the laparoscopic approach is summarized in **Figure 1**. Endoscopic ultrasonography (EUS) (5 MHz; Olympus, Tokyo, Japan) was performed to further exclude liver invasion before operating. The patients who had GBC with suspected liver invasion on EUS underwent conventional open resection. The patients without evidence of liver invasion on both CT and EUS underwent the laparoscopic approach.

After creating the pneumoperitoneum, the whole abdomen was carefully inspected, including the liver and hepatoduodenal ligament. Laparoscopic ultrasonography (LUS) (7.5 MHz; Aloka, Tokyo, Japan) was then performed on the whole liver by experienced radiologists (Y.H.K. and K.H.L.) for further excluding GBC with liver invasion and for detecting occult liver metastasis. When liver invasion was diagnosed on LUS, conversion to laparotomy was performed. The patients without evidence of liver invasion on LUS underwent LC. After the gallbladder was resected out, intraoperative frozen biopsy was performed to confirm the presence of carcinoma, the depth of invasion, the presence of liver invasion, and the involvement of the cystic duct margin. Surgery was completed when the diagnosis was benign disease, and additional locoregional laparoscopic lymphadenectomy (LLA) was performed when the diagnosis was malignant disease.

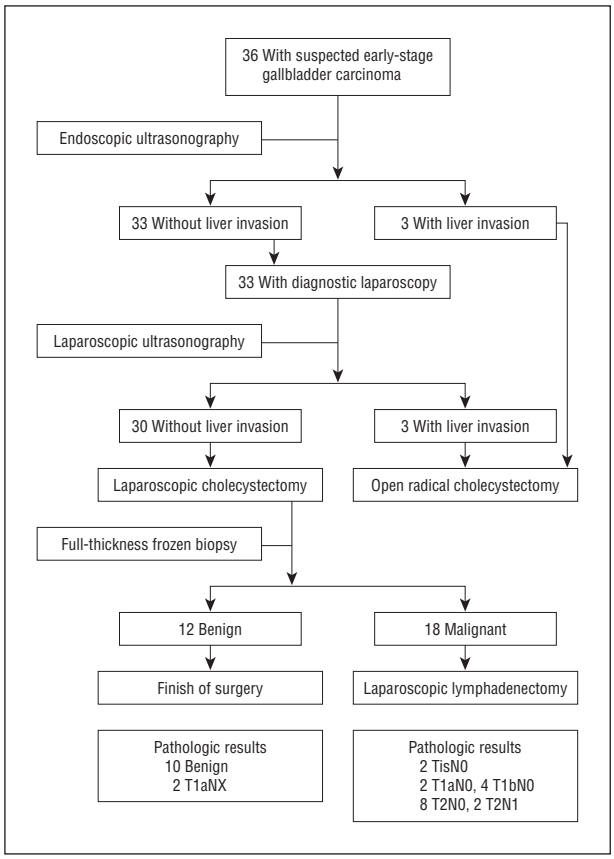

Figure 1. Summary of the treatment algorithm for the laparoscopic approach for 36 patients with suspected early-stage gallbladder carcinoma, defined as suspected T1 or T2 gallbladder carcinoma without liver invasion on the preoperative computed tomographic scan.

Figure 2. Laparoscopic view of the operative field after completion of node dissection.

OPERATIVE TECHNIQUE OF LAPAROSCOPIC APPROACH FOR SUSPECTED EARLY-STAGE GBC

A 30° laparoscope or flexible laparoscope was used. During LC in patients with suspected early-stage GBC, the gallbladder, including about 2 mm of the thin liver tissue adhered to the gallbladder, was carefully resected so as not to spill the potentially malignant bile and not to expose the subserosal layer of the gallbladder. For LC, 3 ports were usually used in the standard manner. Once the specimen had been completely detached, it was inserted into a protective bag and extracted through the umbilical port site. The extent of LLA was the pericholedochal, hilar, periportal, and common hepatic nodes (**Figure 2**). For LLA, 1 or 2 additional 5-mm ports were inserted on the right subcostal area. A lymphadenectomy was performed using ultrasonic shears (harmonic scalpel [Ethicon, Cincinnati, Ohio] or SonoSurg [Olympus]). Lymph node dissection around the hepatoduodenal ligament was performed, and then

©2010 American Medical Association. All rights reserved.
Downloaded From: http://archsurg.jamanetwork.com/ on 04/30/2017

Table. Histological Results of 30 Patients With Completed Laparoscopic Cholecystectomy

Histological Results	Patients, No.
R0 resection	30
Benign	10
Carcinoma	20
T stage	
Tis	2
T1	8
T2	10
T3 or T4	0
N stage	
N0	16
N1	2
NX	2
Stage	
IA	10
IB	8
IIA	0
IIB	2
III or IV	0
Differentiation	
Well	14
Moderate	4
Poor	2
Gross type	
Papillary	12
Nodular	7
Flat	1

dissection around the common hepatic artery was done. After careful hemostasis, a silastic drain was inserted and the wound was closed in layers.

Operation with nodal dissection, negative surgical margins around the gallbladder, and no apparent unresectable metastatic lymph nodes was considered a curative resection. Clinical staging of disease was performed according to the American Joint Committee on Cancer staging system.[11]

FOLLOW-UP PROGRAM AND DIAGNOSIS OF RECURRENCE

The routine follow-up program consisted of physical examinations and laboratory tests, including determining the carcinoembryonic antigen and CA19-9 levels. The laboratory tests were performed once every 3 months for the first 2 years and then biannually for the next 3 years. Chest radiography and abdominopelvic CT were also performed as part of the routine follow-up protocol.

RESULTS

INTENTION-TO-TREAT ANALYSIS OF LAPAROSCOPIC APPROACH FOR EARLY-STAGE GBC

The laparoscopic approach for early-stage GBC was prospectively performed beginning May 1, 2004, at our hospital. Of the 63 patients who underwent operation for preoperatively diagnosed resectable GBC from May 10, 2004, to October 9, 2007, 36 patients were eligible for the laparoscopic approach. Among these 36 patients, 3 were diagnosed as having direct liver invasion on EUS, and this invasion was not detected on preoperative CT. These 3 patients underwent conventional open surgery with curative intent. Consequently, the 33 remaining patients suspected to have early-stage GBC without liver invasion were treated by laparoscopy.

During the laparoscopic approach, 3 patients were additionally diagnosed as having direct liver invasion on LUS, and this was not detected on CT or EUS. Open conversion for conventional radical cholecystectomy, including lymph node dissection and central hepatectomy (segments 4a and 5), was performed for these 3 patients. There was no evidence of liver metastasis or carcinomatosis in the remaining 30 patients after performing diagnostic laparoscopy and LUS. These 30 patients underwent LC.

Intraoperative frozen biopsy revealed no evidence of carcinoma in 12 patients, and GBC was found in 18 patients. The 12 patients diagnosed as having benign lesions received no further procedures. The remaining 18 patients suspected to have early-stage GBC underwent LLA.

INTRAOPERATIVE RESULTS OF LLA

Of the 18 patients who underwent LLA, there were 5 men and 13 women with a median age of 69 years (age range, 51-76 years). During the laparoscopic procedure, no bile spillage occurred due to perforation of the gallbladder. The median operative time and blood loss in these 18 patients were 190 minutes (range, 90-277 minutes) and 50 mL (range, 10-400 mL), respectively.

Intraoperative complications occurred in 2 of the 18 patients who underwent LLA. Conversion to laparotomy occurred in 1 patient. This patient exhibited bleeding from a torn branch of the main portal vein during node dissection. After making a subcostal incision, repair of the injured portal vein was performed. Another patient experienced left hepatic duct injury during LLA. Laparoscopic intracorporeal repair of the injured duct with T-tube insertion was performed. Cholangiography via the T-tube on the seventh postoperative day showed no bile duct stricture or leakage, and the T-tube was then removed. After follow-up during 19 months, no long-term complications were observed in this patient. No intraoperative mishaps occurred in the 12 patients who underwent cholecystectomy alone.

PATHOLOGIC RESULTS

The postoperative pathologic diagnoses for the 30 patients who completed laparoscopic surgery are summarized in the **Table**. The pathologic results of the 12 patients who received LC alone included adenomyomatosis (n=1), xanthogranulomatous cholecystitis (n=1), chronic cholecystitis (n=2), tubular adenoma (n=6), and T1aNX carcinoma (n=2). For 2 patients whose postoperative diagnosis has changed from benign to T1a GBC, no repeat resection was performed because the operations in these patients were considered to be curative resection.

The pathologic results of the 18 patients who received LLA included TisN0 (n=2), T1aN0 (n=2), T1bN0 (n=4), T2N0 (n=8), and T2N1 (n=2). Most of the car-

©2010 American Medical Association. All rights reserved.
Downloaded From: http://archsurg.jamanetwork.com/ on 04/30/2017

cinomas in the patients with GBC were well differentiated and of the papillary type.

The absence of hepatic invasion in all 30 patients who underwent the laparoscopic approach was confirmed pathologically. Therefore, the negative predictive values for determining whether there was hepatic invasion were 83.3% (30 of 36 patients) on CT, 90.9% (30 of 33 patients) on CT and EUS, and 100% (30 of 30 patients) on CT, EUS, and LUS.

POSTOPERATIVE OUTCOMES

The median number of retrieved lymph nodes in the 18 patients who received LLA was 8 (range, 4-21). The tumors ranged from 1.4 to 7.5 cm. All of the operations in all of these patients were considered curative resection. Therefore, repeat resection was not performed in any of these patients.

Postoperative complications occurred in 3 of the 18 patients who underwent LLA (16.7%). The complications included symptomatic fluid collection at the gallbladder fossa (n=1), postoperative transient blood drainage via the indwelling drain (n=1), and voiding difficulty (n=1). However, all were conservatively treated without radiological intervention or reoperation. The median postoperative hospital stay was 4 days (range, 3-11 days). After a median follow-up of 27 months (range, 15-57 months), no tumor recurrence or port site metastasis was observed in any of the 18 patients who underwent LLA, and all of the patients survived without any evidence of recurrent disease.

COMMENT

Although there are many reports on the results of incidentally discovered GBC during or after LC[12,13] and on the laparoscopic staging for patients with advanced GBC,[14,15] the outcome of the intentional laparoscopic treatment approach for GBC has not yet been reported. The laparoscopic approach for suspected early-stage GBC without liver invasion has 2 potential advantages. First, if the laparoscopic approach is potentially equivalent to open radical cholecystectomy from the oncologic point of view, the laparoscopic approach could be an alternative treatment option for patients with early-stage GBC. Laparoscopic lymphadenectomy is now widely applied for treating colon cancer and gastric cancer. The efficacy of LLA for these 2 malignant neoplasms has been reported to be adequate in terms of the oncologic aspects, and we have accumulated experience with LLA for treating patients with early-stage gastric cancer.[16] The LLA requires more experience than open lymphadenectomy because this operative procedure is technically demanding. Ultrasonic shears were used for LLA in our institution. Use of ultrasonic shears may cause adverse effects on medium-sized vessels, causing thrombus or late occlusion.[17] Therefore, it might be reasonable and safer to convert to open lymphadenectomy when frozen section confirms carcinoma unless the surgeon has significant experience and expertise in advanced laparoscopic dissection. By performing a laparoscopic procedure, the patients can benefit from the advantage of the minimal invasiveness of laparoscopic surgery. Second, some patients with preoperatively suspected GBC can be confirmed to have benign gallbladder disease, such as adenomyomatosis or xanthogranulomatous cholecystitis, on the postoperative pathologic report.[18] Therefore, the laparoscopic approach for suspected early-stage GBC can avoid unnecessary open surgery in those patients who are finally confirmed to have benign lesions.

Our results show that all 30 patients suspected to have early-stage GBC without liver invasion were proven to have benign disease or carcinoma with a T stage of 2 or less. Moreover, the patients who were finally discovered to have benign lesions avoided unnecessary open surgery. All 30 cholecystectomies were performed without any bile spillage due to gallbladder perforation during LC. Only 1 technical failure occurred during LLA. The complication rate (16.7%) and the postoperative hospital stay (median, 4 days) were acceptable. The 5-year survival rates of the patients with pT2 GBC have been reported to be 87.1% for those with pN0 lesions and 55.7% for those with pN1 lesions.[19] The incidence of lymph node metastasis may be as high as 39% to 54% in patients with pT2 disease.[20] Therefore, further study to verify the adequacy of LLA is needed. Although the follow-up period was not long enough to determine the long-term outcome, there was no recurrence or metastasis in any patients, including the 10 patients with pT2 GBC.

A prerequisite for the proposed treatment algorithm (Figure 1) is high-quality radiological studies to accurately exclude hepatic invasion. Although CT and EUS are widely used for detecting hepatic invasion, hepatic invasion was undetected in 3 of 33 patients in our study. With combined CT, EUS, and LUS, the negative predictive value of our radiological studies for excluding hepatic invasion reached 100%. We used CT as the initial imaging method because CT can be readily performed and because virtually all of the patients suspected to have GBC need CT for staging purposes. However, hepatic invasion can be undetected on CT if the invasion is focal and shallow.[21] With the advent of EUS, more centers have incorporated EUS as a preoperative staging modality. This tool improves the sensitivity for staging GBC from 74% to 90% when compared with making the diagnosis using transabdominal ultrasonography alone.[22] Although there are only a few reports on the accuracy and role of LUS for staging GBC,[14,15] LUS is likely to be the most accurate imaging test for T staging when considering its outstanding spatial resolution for depicting multiple layers within the gallbladder wall.

Cholecystectomy alone for treating patients with pT2 GBC is not enough because a considerable proportion of the patients with pT2 GBC have a possibility of positive lymph node metastasis,[23] and adjunctive radical surgical resection that is performed either at the time of cholecystectomy or afterward significantly increases patients' survival.[13] Many authors have already reported lymph node dissection as a recommended surgical procedure to improve the survival of patients with GBC.[24,25]

©2010 American Medical Association. All rights reserved.
Downloaded From: http://archsurg.jamanetwork.com/ on 04/30/2017

Moreover, because pT2 GBC has no direct invasion to adjacent organs, a potentially curative resection can be achieved without hepatectomy and extrahepatic bile duct resection provided that the involved lymph nodes can be adequately dissected.[19] Although simple cholecystectomy alone for patients with pT1 GBC can achieve satisfactory surgical results,[12] frozen biopsy has limited accuracy for the T staging of GBC.[26] Concerning understaging GBC with a T stage of 2 or greater as T1 GBC, we performed lymph node dissection for all GBC diagnosed via frozen biopsy. Furthermore, some researchers argue for the necessity of extended cholecystectomy for treating T1b lesions.[4,27] Little has been reported concerning the accuracy of a frozen section diagnosis of the gallbladder. The intraoperative frozen tissue diagnosis is fairly reliable in determining whether lesions are malignant or benign, but the frozen tissue diagnosis and the final diagnosis are sometimes not identical.[8] In this series, the postoperative diagnosis was changed from benign to malignant (T1NX) for 2 patients.

There could be concerns about a positive tumor margin of the gallbladder and cystic duct. A negative margin should be confirmed by intraoperative frozen biopsy, although there was no case with a positive margin in this series. If a positive margin is encountered, additional liver resection or extrahepatic bile duct resection should be considered with performing an open conversion procedure. Gallbladder perforation during LC may cause tumor to spread into the peritoneal cavity, and this may also occur during open surgery. When early-stage GBC suspicion exists before surgery, necessary oncologic precautions can be enforced. The reasons for tumor dissemination and port implantation after LC for preoperatively unsuspected GBC are gallbladder manipulation with forceps, perforation, and extraction without a bag. If GBC is preoperatively suspected, one should pay as close attention as possible to not perforate the gallbladder and must use a protective bag during the extraction of resected gallbladder.

To our knowledge, this study is the first to report the feasibility of intentional laparoscopic treatment for patients with early-stage GBC without evidence of liver invasion. The laparoscopic approach could be an alternative treatment option when early-stage GBC without liver invasion is preoperatively diagnosed or if this is incidentally discovered during LC.

In conclusion, our results showed that the laparoscopic approach is technically feasible and the interim outcome is acceptable for highly selected patients who have early-stage GBC without liver invasion. However, long-term follow-up and prospective randomized trials are needed to confirm our interim results.

Accepted for Publication: February 25, 2009.
Correspondence: Ho-Seong Han, MD, PhD, Department of Surgery, Seoul National University Bundang Hospital, 300 Gumi-dong, Bundang-gu, Seongnam-si, Gyeonggi-do, 463-707, Korea (hanhs@snubh.org).
Author Contributions: *Study concept and design:* Han and Yoon. *Acquisition of data:* Cho. *Analysis and interpretation of data:* Ahn, Kim, and Lee. *Drafting of the manuscript:* Cho, Ahn, and Kim. *Critical revision of the manuscript for important intellectual content:* Han, Yoon, and Lee. *Statistical analysis:* Cho and Lee. *Administrative, technical, and material support:* Yoon and Ahn. *Study supervision:* Han and Kim.
Financial Disclosure: None reported.
Funding/Support: This study was supported by grant A060299 from the Korea Healthcare Technology R&D project, Ministry of Health and Welfare, Republic of Korea.

REFERENCES

1. Dixon E, Vollmer CM Jr, Sahajpal A, et al. An aggressive surgical approach leads to improved survival in patients with gallbladder cancer: a 12-year study at a North American center. *Ann Surg*. 2005;241(3):385-394.
2. Kondo S, Nimura Y, Hayakawa N, Kamiya J, Nagino M, Uesaka K. Extensive surgery for carcinoma of the gallbladder. *Br J Surg*. 2002;89(2):179-184.
3. Ouchi K, Mikuni J, Kakugawa Y; Organizing Committee, The 30th Annual Congress of the Japanese Society of Biliary Surgery. Laparoscopic cholecystectomy for gallbladder carcinoma: results of a Japanese survey of 498 patients. *J Hepatobiliary Pancreat Surg*. 2002;9(2):256-260.
4. Wakai T, Shirai Y, Yokoyama N, Nagakura S, Watanabe H, Hatakeyama K. Early gallbladder carcinoma does not warrant radical resection. *Br J Surg*. 2001; 88(5):675-678.
5. Fong Y, Jarnagin W, Blumgart LH. Gallbladder cancer: comparison of patients presenting initially for definitive operation with those presenting after prior noncurative intervention. *Ann Surg*. 2000;232(4):557-569.
6. Wakai T, Shirai Y, Yokoyama N, Ajioka Y, Watanabe H, Hatakeyama K. Depth of subserosal invasion predicts long-term survival after resection in patients with T2 gallbladder carcinoma. *Ann Surg Oncol*. 2003;10(4):447-454.
7. Yamaguchi K, Chijiiwa K, Saiki S, et al. Retrospective analysis of 70 operations for gallbladder carcinoma. *Br J Surg*. 1997;84(2):200-204.
8. Yamaguchi K, Chijiiwa K, Saiki S, Shimizu S, Tsuneyoshi M, Tanaka M. Reliability of frozen section diagnosis of gallbladder tumor for detecting carcinoma and depth of its invasion. *J Surg Oncol*. 1997;65(2):132-136.
9. Goetze T, Paolucci V. Does laparoscopy worsen the prognosis for incidental gallbladder cancer? *Surg Endosc*. 2006;20(2):286-293.
10. Kondo S, Takada T, Miyazaki M, et al; Japanese Association of Biliary Surgery; Japanese Society of Hepato-Biliary-Pancreatic Surgery; Japan Society of Clinical Oncology. Guidelines for the management of biliary tract and ampullary carcinomas: surgical treatment. *J Hepatobiliary Pancreat Surg*. 2008;15(1):41-54.
11. Greene FL, Page DL, Fleming ID, et al, eds; American Joint Committee on Cancer. *Cancer Staging Manual*. 6th ed. New York, NY: Springer; 2002.
12. Chan KM, Yeh TS, Jan YY, Chen MF. Laparoscopic cholecystectomy for early gallbladder carcinoma: long-term outcome in comparison with conventional open cholecystectomy. *Surg Endosc*. 2006;20(12):1867-1871.
13. Shih SP, Schulick RD, Cameron JL, et al. Gallbladder cancer: the role of laparoscopy and radical resection. *Ann Surg*. 2007;245(6):893-901.
14. Agrawal S, Sonawane RN, Behari A, et al. Laparoscopic staging in gallbladder cancer. *Dig Surg*. 2005;22(6):440-445.
15. Weber SM, DeMatteo RP, Fong Y, Blumgart LH, Jarnagin WR. Staging laparoscopy in patients with extrahepatic biliary carcinoma: analysis of 100 patients. *Ann Surg*. 2002;235(3):392-399.
16. Lee JH, Han HS, Lee JH. A prospective randomized study comparing open vs laparoscopy-assisted distal gastrectomy in early gastric cancer: early results. *Surg Endosc*. 2005;19(2):168-173.
17. Yoon YS, Lee KH, Han HS, Cho JY, Ahn KS. Patency of splenic vessels after laparoscopic spleen and splenic vessel-preserving distal pancreatectomy. *Br J Surg*. 2009;96(6):633-640.
18. Ching BH, Yeh BM, Westphalen AC, Joe BN, Qayyum A, Coakley FV. CT differentiation of adenomyomatosis and gallbladder cancer. *AJR Am J Roentgenol*. 2007;189(1):62-66.
19. Yokomizo H, Yamane T, Hirata T, Hifumi M, Kawaguchi T, Fukuda S. Surgical treatment of pT2 gallbladder carcinoma: a reevaluation of the therapeutic effect of hepatectomy and extrahepatic bile duct resection based on the long-term outcome. *Ann Surg Oncol*. 2007;14(4):1366-1373.
20. Gourgiotis S, Kocher HM, Solaini L, Yarollahi A, Tsiambas E, Salemis NS. Gallbladder cancer. *Am J Surg*. 2008;196(2):252-264.
21. Kim SJ, Lee JM, Lee JY, et al. Accuracy of preoperative T-staging of gallbladder carcinoma using MDCT. *AJR Am J Roentgenol*. 2008;190(1):74-80.
22. Pandey M, Sood BP, Shukla RC, Aryya NC, Singh S, Shukla VK. Carcinoma of

©2010 American Medical Association. All rights reserved.
Downloaded From: http://archsurg.jamanetwork.com/ on 04/30/2017

the gallbladder: role of sonography in diagnosis and staging. *J Clin Ultrasound*. 2000;28(5):227-232.
23. Tsukada K, Kurosaki I, Uchida K, et al. Lymph node spread from carcinoma of the gallbladder. *Cancer*. 1997;80(4):661-667.
24. Kondo S, Nimura Y, Hayakawa N, Kamiya J, Nagino M, Uesaka K. Regional and para-aortic lymphadenectomy in radical surgery for advanced gallbladder carcinoma. *Br J Surg*. 2000;87(4):418-422.
25. Shimada H, Endo I, Togo S, Nakano A, Izumi T, Nakagawara G. The role of lymph node dissection in the treatment of gallbladder carcinoma. *Cancer*. 1997;79(5):892-899.
26. Azuma T, Yoshikawa T, Araida T, Takasaki K. Intraoperative evaluation of the depth of invasion of gallbladder cancer. *Am J Surg*. 1999;178(5):381-384.
27. Wagholikar GD, Behari A, Krishnani N, et al. Early gallbladder cancer. *J Am Coll Surg*. 2002;194(2):137-141.

INVITED CRITIQUE

Planned Laparoscopic Approach for Early-Stage Gallbladder Cancer

The Glass Is One-Third Full

Preoperative suspicion of cancer is generally considered a contraindication to LC. However, many patients are found to have benign or pT1a disease, for which LC alone is sufficient. For pT1b or pT2 disease, where nodal metastases are more likely, LC alone is inadequate and portal lymphadenectomy is recommended for staging and tumor clearance. While the role of extended resection of the gallbladder bed for pT1b or pT2 disease can be debated, it is possible that accurate preoperative staging could allow definition of a subset of patients with suspected early-stage GBC in whom a planned initial laparoscopic approach might be reasonable.

This prospective intention-to-treat study addresses the accuracy of preoperative staging for patients with early-stage GBC in whom a planned LC might be contemplated. The results indicate that preoperative CT alone is inadequate; subsequent ultrasonographic evaluation of patients with T1 or T2 disease based on CT criteria revealed invasive disease in 6 of 36 patients (16.7%). Laparoscopic ultrasonography identified invasive lesions missed by EUS, and thus expertise in LUS appears critical to operative planning. By the combination of CT, EUS, and LUS, about one-third of patients were determined to have benign disease; these patients clearly benefited from the planned laparoscopic approach. For the two-thirds of patients found to harbor a malignant neoplasm, the laparoscopic approach to lymphadenectomy was feasible but risky; major hemorrhage or bile duct injury occurred in 2 of 18 patients. It may be more prudent for patients found to have malignant disease by intraoperative frozen section to undergo conversion to open operation. In the zeal to offer laparoscopic surgery to the subset of patients with early-stage GBC who do not require radical resection, surgeons should balance the risk of rendering a potentially curative situation incurable through operative error or inadequate tumor clearance.

Jeffrey B. Matthews, MD

Author Affiliations: Department of Surgery, University of Chicago, Chicago, Illinois.
Correspondence: Dr Matthews, Department of Surgery, University of Chicago, 5841 S Maryland Ave, MC5029, Chicago, IL 60637 (jmatthews@uchicago.edu).
Financial Disclosure: None reported.

©2010 American Medical Association. All rights reserved.
Downloaded From: http://archsurg.jamanetwork.com/ on 04/30/2017