

Total Extraperitoneal Laparoscopic Inguinal Hernia Repair Without Mesh Fixation

Prospective Study With 1-Year Follow-up Results

Evangelos Messaris, MD, PhD; Guy Nicasri, MD; Stanley J. Dudrick, MD

Objective: To determine the outcomes of patients undergoing total extraperitoneal inguinal hernia repair without fixation of the mesh.

Design: Prospective cohort.

Setting: Community teaching hospital.

Patients: A total of 274 consecutive patients were included in the study group.

Interventions: All operations were performed by the same surgeon with the patients under general anesthesia in an outpatient setting. A preformed polyester mesh (Parietex; Covidien, Mansfield, Massachusetts) was used in all cases without any fixation.

Main Outcome Measures: All patients were prospectively followed up at 2 weeks, 1 month, and 1 year after surgery. Operative morbidity, chronic pain, and hernia recurrence were recorded.

Results: Two hundred seventy-four consecutive patients underwent 311 total extraperitoneal inguinal hernia repairs. No conversions were made to open hernia repairs. No recurrences were found at the 12-month follow-up visit. There were 19 inguinal seromas (6.1%) identified at 2 weeks, but only 7 (1.9%) remained at 1 month, and none at 1 year. No wound infections, scrotal hematomas, or other perioperative complications were reported. Two hundred thirty-six patients used fewer than the 30 prescribed tablets for pain control, while 23 patients requested a refill, 12 of whom had seromas ($P < .01$). At 12 months, no patient was taking pain relief medication; however, 8 patients reported occasional discomfort in the groin, and 1 patient reported occasional umbilical discomfort.

Conclusion: This single general surgeon experience supports total extraperitoneal inguinal hernia repair without mesh fixation as a safe, effective procedure with low morbidity and no evidence of recurrence at the 1-year follow-up visit.

Arch Surg. 2010;145(4):334-338

THE LAPAROSCOPIC APPROACH for inguinal hernia repair was first reported by Ger,¹ who performed a high ligation of the sac without mesh placement. In the early 1990s, a variety of transabdominal laparoscopic approaches were reported, with the transabdominal preperitoneal approach and the intraperitoneal onlay mesh techniques being the most common.² Because of reports of high recurrence rates, the intraperitoneal onlay mesh technique quickly fell out of favor. In 1993, McKernan and Laws³ described the laparoscopic total extraperitoneal (TEP) approach. Total extraperitoneal repair was developed because of concern for possible complications

associated with intra-abdominal access, which was required for the transabdominal preperitoneal approach.⁴ The TEP method allows access to the preperitoneal space and avoids the need for a peritoneal incision.³ In an extraperitoneal laparoscopic repair, access to the preperitoneal space is achieved with a dissecting balloon, a laparoscope, or blunt dissection and/or carbon dioxide dissection, while the dissection is visualized from the extraperitoneal cavity. A mesh prosthesis is inserted into the preperitoneal space. Many technical variations exist in fixation (tacks, staples, or fibrin glue) or nonfixation methods and mesh configuration.⁵⁻⁹

The mechanisms of inguinal hernia recurrence after laparoscopic repair have been

Author Affiliations:

Departments of Surgery, Rhode Island Hospital (Dr Messaris) and Memorial Hospital (Dr Nicasri), The Warren Alpert Medical School, Brown University, Providence, Rhode Island, and Saint Mary's Hospital, Waterbury, Connecticut (Dr Dudrick).

studied by many investigators and are related mostly to technique.¹⁰⁻¹³ As techniques have improved and surgeons have gained experience, recurrence rates have declined. One of the most common reasons for recurrence is incomplete dissection of the preperitoneal space and inadequate overlap of the hernia defect from placement of a small mesh.^{14,15} Furthermore, the nonfixated mesh theoretically may migrate and be the cause of early recurrence. Two randomized studies demonstrated no significant increase in recurrence after TEP repair without fixation of the mesh.^{16,17} Furthermore, nonfixation was associated with lower cost, decreased use of postoperative analgesia, and lower incidence of urinary retention. At our institution, we have been using a preformed mesh without mechanical fixation for about 4 years. In an effort to address the issues of hernia recurrence and perioperative morbidity, we report the outcomes in cases involving patients who underwent TEP inguinal hernia repair without fixation of the mesh.

METHODS

A prospective trial of elective laparoscopic extraperitoneal inguinal hernia repairs was conducted between August 2004 and December 2006 in a community teaching hospital. Patients consented to the study during initial consultation. The inclusion criterion was a clinically diagnosed primary or recurrent inguinal hernia. International and out-of-town patients were excluded because of practical concerns about long-term follow-up. Furthermore, emergency cases, patients with strangulated hernias, patients with concurrent femoral hernias, patients younger than 18 years old, and patients with previous open prostate surgery or an inability to undergo general anesthesia because of comorbidities were excluded from the study. All patients were offered the alternative of the open approach for the repair of their inguinal hernia. The study was approved by the board of directors of the hospital. On entry into the study, the patients were interviewed and examined in the clinic.

All procedures were performed on an outpatient basis at a community hospital, with discharge on the day of the operation. All operations were performed by the same surgeon (G.N.) with the patient under general anesthesia. The surgeon had 10 years of experience in basic and advanced laparoendoscopic procedures. The patients were included in a follow-up protocol and were reexamined 2 weeks, 1 month, and 1 year after surgery. Follow-up included questioning for the presence or absence of pain and, if pain was present, whether it was minimal, moderate, or severe. All patients underwent a physical examination by the operating surgeon. The examination consisted of evaluation of the inguinal region with the patient in both prone and standing positions with Valsalva maneuvers. Patients who missed their 12-month appointment ($n=19$ [6.9%]) were interviewed by telephone regarding their level of pain and any signs of recurrence. The parameters recorded in all patients were demographic data, hernia type, side of hernia, previous surgery, postoperative complications, operating time, ambulatory or admission surgery, time to return to regular activities, and postoperative pain. Chronic pain was defined as any inguinal, scrotal, or midhigh pain that remained 1 month after surgery. All patients were examined for any recurrence; in case of seromas, an ultrasonogram was obtained to confirm the diagnosis and to differentiate the seroma from a recurrence of the inguinal hernia.

SURGICAL TECHNIQUE

After the patient was under general endotracheal anesthesia, a single dose of cephazolin was administered. A Foley catheter was not used, as all patients were asked to void in the preoperation area. The skin incision was made at the inferior aspect of the umbilicus. Dissection was carried down to the anterior fascia of the rectus muscle just lateral to the midline. Following the anterior rectus fascia incision, blunt dissection was used to sweep the rectus muscle laterally off the posterior fascia from the midline. The dissecting balloon was placed in the space between the rectus muscle anteriorly and the posterior fascia and directed down to the pubis. The dissector was inflated under direct visualization. In each case, the pubis, the Cooper ligament, and the rectus muscle fibers were identified through the balloon, after which the balloon was deflated and removed. A standard Hasson-type blunt port was placed in this extraperitoneal space, and carbon dioxide was insufflated to reach a maximum pressure of 10 to 12 mm Hg. Two 5-mm trocars were placed in the lower midline between the rectus muscles. After identification of the inferior epigastric vessels superiorly, the Cooper ligament medially, and the ileopubic tract laterally, the pelvic wall was inspected to identify the presence of a direct, an indirect, and/or a femoral hernia. After identification of the hernia defect(s), the hernia sac was reduced completely, with particular attention given to reducing the indirect sac off the cord structures. A space was then created behind the cord structures superficial to the underlying iliac lymph node bed for future passage of the mesh. During dissection in the groin area, some openings to the peritoneum might occur. In all cases, the hole was closed using an endoloop ligature (2-0 polyglactin 910 [Vicryl; Ethicon, Inc, Somerville, New Jersey]), and, when needed, the peritoneal cavity was decompressed with a Veress needle.

A preformed polyester mesh (Parietex; Covidien, Mansfield, Massachusetts) was used for the repair. Its posterior leaflet is passed from a medial to lateral direction under the cord structures, with care taken to cover the internal ring both laterally and superiorly. The attached anterior leaflet, which had been previously collapsed with a suture, is positioned such that its lateral aspect is tucked along the ileopubic tract laterally and its medial aspect is tucked below the Cooper ligament medially (**Figure**). Once the anterior leaflet is correctly positioned, the preplaced suture is removed, allowing the anterior leaflet to spring open, covering the direct, indirect, and femoral spaces as well as the posterior leaflet. When the mesh is correctly positioned, carbon dioxide is slowly released from the preperitoneal space (under direct visualization), allowing the peritoneum to "sandwich" the mesh in place against the abdominal wall.

After surgery, the patients' diets were advanced as tolerated, and no activity restrictions were given. Patients were allowed to return to any activity as comfort allowed. A prescription for acetaminophen/hydrocodone was given to the patients, who were usually able to switch to anti-inflammatories a few days after surgery. All patients were asked to contact the surgeon if bruising and swelling of the groin, penis, or scrotum developed. Urinary retention in the first 24 hours was also reported.

STATISTICAL ANALYSIS

Associations between categorical or dichotomous variables were tested using the χ^2 test. Continuous variables were compared using the t test. $P < .05$ was considered statistically significant.

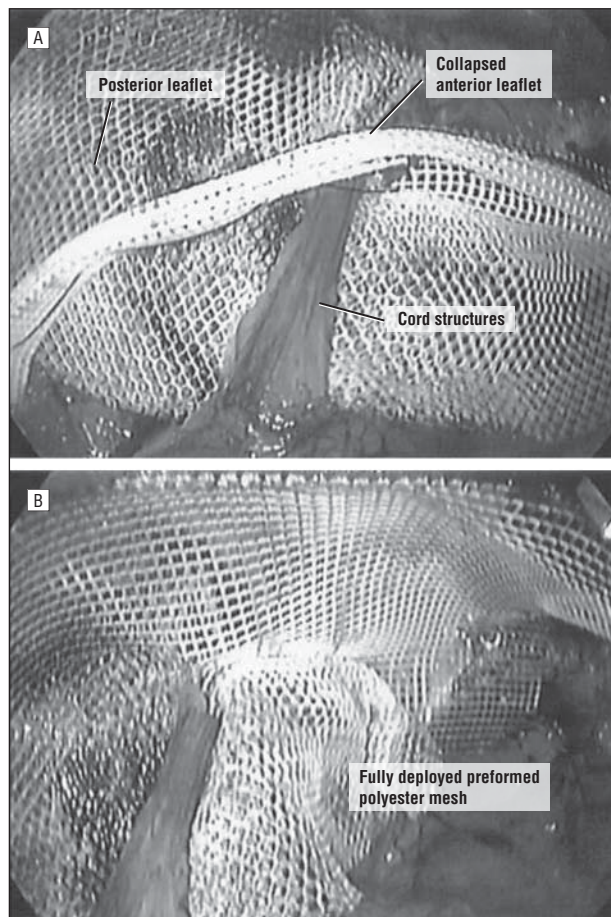


Figure. Placement of the preformed polyester mesh (Parietex; Covidien, Mansfield, Massachusetts). The mesh is initially placed under the cord structures (A), and then the anterior leaflet springs open, covering the direct, indirect, and femoral spaces as well as the posterior leaflet (B).

RESULTS

A total of 328 elective inguinal hernia repairs were performed in 286 patients during the 2-year study period. The study included 274 patients; 12 patients (3.6%) with unilateral hernias were excluded. The latter patients were not considered candidates for TEP inguinal hernia repair because of previous prostate surgery (4 patients) or significant comorbidities (6 patients with severe chronic obstructive pulmonary disease and 2 with severe coronary artery disease) that made them high risk for general anesthesia. Instead, these patients underwent open repairs. In the remaining 274 patients, 311 TEP procedures were performed successfully. The age of the patients ranged from 16 to 82 years, and most were males (83%) with unilateral (88%), primary (84%), or indirect (68%) inguinal hernias. The patient characteristics are presented in the **Table**. The mean (SD) operative time was 45.1 (6.1) minutes for unilateral repairs and 54.6 (8.5) minutes for bilateral repairs ($P < .001$).

OUTCOME

No conversions to open hernia repairs were required. No hernia recurrences were found at the 12-month

Table. Patient Characteristics

Characteristic	Value
No. of patients	274
No. of hernias	311
Patients with 1 y of follow-up, No. (%)	262 (96)
Median age, (range), y	43 (18-82)
Male sex, No. (%)	257 (83)
Type of hernia, No. (%)	
Direct	96 (30)
Indirect	186 (60)
Mixed	32 (10)
Primary hernia, No. (%)	267 (86)
Recurrence of hernia, No. (%)	44 (14)
Unilateral repair, No. (%)	273 (88)
Bilateral repair, No. (%)	38 (12)

follow-up visit. Only minor complications were noted. Two male patients developed urinary retention, 1 of whom required hospitalization and insertion of a bladder catheter. The patient was discharged 24 hours later after a successful voiding trial. Seroma formation in the preperitoneal inguinal space was the most frequent postoperative complication. A total of 19 inguinal seromas (19 of 311 [6.1%]) were identified in 17 patients (2 bilateral seromas). Most of them ($n=11$ [57%]) were noticed during repairs of direct hernias. Each case was confirmed with ultrasonography to rule out recurrence. Of the 19 inguinal seromas (6.1%) that were identified at 2 weeks, only 7 (1.9%) remained at 1 month, and none at 1 year. The 6 patients with seromas at 1 month were reexamined 3 months after surgery, and there was complete resolution of the seromas. No wound infections, scrotal hematomas, or other perioperative complications were reported. All the patients returned to work or their regular activities within 2 weeks of surgery. Ten of the patients were college athletes, and they also returned to their regular training schedule 2 weeks after surgery.

PAIN CONTROL

At 12 months, all patients reported no pain at the surgical site and complete resolution of the preoperative symptoms. However, 12 patients (4%) reported intermittent discomfort in the groin area that was of little concern to them and needed no medication to resolve. They described the pain as infrequent twinges of discomfort occurring fewer than 3 times per month and as irrelevant to any activities. None of them had a recurrence of the hernia, and they reported normal activities with no restriction because of the discomfort. All reported to be happy with their repair. Most patients ($n=236$ [86%]) used fewer than the 30 prescribed tablets for pain control for an average of 2.5 days after surgery. On the other hand, 23 patients requested a refill, 12 of whom (52%) had seromas ($P < .001$). At 1 month, no patients were taking pain relief medications, not even the 6 patients who still had seromas.

This single-surgeon experience supports TEP inguinal hernia repair without mesh fixation as a safe, effective procedure with low morbidity and no evidence of early recurrence. For procedures such as cholecystectomy and Nissen fundoplication, the laparoscopic approach was quickly adopted as the preferred technique within a few years of introduction. The optimal operative approach for inguinal hernia repair is still debatable.¹⁸ Most techniques involve reinforcement of the inguinal floor with a synthetic or biologic material to obtain a tension-free repair. Evidence suggests that the routine use of mesh for most inguinal hernias is important. In our case series, we used a preformed polyester mesh that allowed smooth layering over the inguinal floor and femoral vessels, with less mesh folding when the peritoneum approximated itself against the mesh.¹⁹ The pore size and elasticity of the mesh are variable: large and lax inferiorly and small and stiff superiorly, encouraging good ingrowth of surrounding tissue into the mesh.

Several anchoring techniques of the mesh have been described using tacs, staples, coils, sutures, and glue.^{5,6,8} Mesh anchoring has been associated with increased perioperative complications (injury to vessels or nerves) and increased temporary or permanent postoperative pain.²⁰⁻²² Therefore, if nonfixation of the mesh does not increase the recurrence rate, it may be a preferred approach. Two randomized studies showed that nonfixation of the mesh is not associated with increased hernia recurrence rate and actually reduces the cost and the postoperative complications compared with mesh fixation techniques.^{17,23} The slit in the preformed mesh used in this study is placed around and behind the spermatic cord, providing some form of fixation and thus preventing mesh migration after preperitoneal desufflation. Recently 2 large case series of TEP repairs with no mesh fixation reported recurrence rates of less than 0.3%.^{16,24} No early 1-year recurrences were noted in our study group, suggesting that nonfixation of the mesh does not increase the recurrence rate. Furthermore, the patients did not report severe, intractable pain in any case. Groin discomfort requiring prolonged use of analgesics (>2 weeks) was present in 15% of the cases, and most of the discomfort was associated with seroma formation. Furthermore, cases with no fixation reduced the operating room costs by \$350 to \$450 compared with cases with mesh fixation involving the use of tacs, staples, coils, sutures, or glue.

Postoperative seroma formation in the inguinal area was the leading complication, appearing in 6% of the study group. The overall incidence of seroma formation has been reported at 7% for TEP inguinal hernia repairs.²⁵ The overall postoperative recovery of the patients was not influenced by the development of seromas; however, additional analgesics were prescribed for these patients. The seromas resolved spontaneously by an average of 2 months after surgery. Other studies have identified the large hernia defect and an extension of the hernia into the scrotum as independent risk factors for seroma formation.²⁵

All cases were closely observed, and no aspiration or oral lysozyme was used.

Open mesh-based repairs are considered easier to learn and to teach than laparoscopic repairs.²⁶ Although there is justifiable concern that laparoscopic inguinal hernia repairs may be associated with an increased recurrence rate, this may not be true in cases involving experienced laparoscopic hernia surgeons. The direct costs for laparoscopic repairs are more than those for open repairs, but they may be largely offset from a societal perspective by a quicker return to normal activity and work.²⁷ For recurrent and bilateral inguinal hernias, the laparoscopic approach to repair seems to have more obvious benefits and may be the technique of choice.²⁶ Total extraperitoneal laparoscopic inguinal hernia repair without mesh fixation is a safe technique with a very low recurrence rate and a low prevalence of chronic pain and can be achieved by general laparoscopists and not only in highly specialized hernia centers.

Accepted for Publication: April 23, 2009.

Correspondence: Evangelos Messaris, MD, PhD, Rhode Island Hospital, 593 Eddy St, Providence, RI 02903 (emessaris@brown.edu).

Author Contributions: *Study concept and design:* Messaris and Nicastrì. *Acquisition of data:* Messaris and Nicastrì. *Analysis and interpretation of data:* Messaris, Nicastrì, and Dudrick. *Drafting of the manuscript:* Messaris and Nicastrì. *Critical revision of the manuscript for important intellectual content:* Nicastrì and Dudrick. *Statistical analysis:* Messaris and Nicastrì. *Administrative, technical, and material support:* Nicastrì and Dudrick. *Study supervision:* Nicastrì and Dudrick.

Financial Disclosure: None reported.

Previous Presentation: This study was presented as a poster at the 89th Annual Meeting of the New England Surgical Society; September 27, 2008; Boston, Massachusetts.

REFERENCES

- Ger R. Laparoscopic hernia operation [in German]. *Chirurg*. 1991;62(4):266-270.
- Filipi CJ, Fitzgibbons RJ Jr, Salerno GM, Hart RO. Laparoscopic herniorrhaphy. *Surg Clin North Am*. 1992;72(5):1109-1124.
- McKernan JB, Laws HL. Laparoscopic repair of inguinal hernias using a totally extraperitoneal prosthetic approach. *Surg Endosc*. 1993;7(1):26-28.
- Wake BL, McCormack K, Fraser C, Vale L, Perez J, Grant AM. Transabdominal pre-peritoneal (TAPP) vs totally extraperitoneal (TEP) laparoscopic techniques for inguinal hernia repair. *Cochrane Database Syst Rev*. 2005;(1):CD004703.
- Felix E, Scott S, Crafton B, et al. Causes of recurrence after laparoscopic hernioplasty: a multicenter study. *Surg Endosc*. 1998;12(3):226-231.
- Katkhouda N, Mavor E, Friedlander MH, et al. Use of fibrin sealant for prosthetic mesh fixation in laparoscopic extraperitoneal inguinal hernia repair. *Ann Surg*. 2001;233(1):18-25.
- Golash V. Technique of suturing the mesh in laparoscopic total extra peritoneal (TEP) repair of inguinal hernia. *Surgeon*. 2004;2(5):264-272.
- Topart P, Vandenbroucke F, Lozac'h P. Tisseel versus tack staples as mesh fixation in totally extraperitoneal laparoscopic repair of groin hernias: a retrospective analysis. *Surg Endosc*. 2005;19(5):724-727.
- Schwab R, Schumacher O, Junge K, et al. Biomechanical analyses of mesh fixation in TAPP and TEP hernia repair. *Surg Endosc*. 2008;22(3):731-738.
- Lamb AD, Robson AJ, Nixon SJ. Recurrence after totally extraperitoneal laparoscopic repair: implications for operative technique and surgical training. *Surgeon*. 2006;4(5):299-307.
- Champault G, Bernard C, Rizk N, Polliand C. Inguinal hernia repair: the choice of prosthesis outweighs that of technique. *Hernia*. 2007;11(2):125-128.

12. Weyhe D, Meurer K, Belyaev O, et al. Do various mesh placement techniques affect the outcome in totally extraperitoneal hernia repair? what is the role of the surgeon? *J Laparoendosc Adv Surg Tech A*. 2007;17(6):749-757.
13. Dulucq JL, Wintringer P, Mahajna A. Laparoscopic totally extraperitoneal inguinal hernia repair: lessons learned from 3,100 hernia repairs over 15 years. *Surg Endosc*. 2009;23(3):482-486.
14. Bringman S, Ek A, Haglind E, et al. Is a dissection balloon beneficial in totally extraperitoneal endoscopic hernioplasty (TEP)? a randomized prospective multicenter study. *Surg Endosc*. 2001;15(3):266-270.
15. Bingener J, Dorman JP, Valdes G. Recurrence rate after laparoscopic repair of recurrent inguinal hernias: have we improved? *Surg Endosc*. 2003;17(11):1781-1783.
16. Garg P, Rajagopal M, Varghese V, Ismail M. Laparoscopic total extraperitoneal inguinal hernia repair with nonfixation of the mesh for 1,692 hernias. *Surg Endosc*. 2009;23(6):1241-1245.
17. Taylor C, Layani L, Liew V, Ghun M, Crampton N, White S. Laparoscopic inguinal hernia repair without mesh fixation: early results of a large randomised clinical trial. *Surg Endosc*. 2008;22(3):757-762.
18. Gould J. Laparoscopic versus open inguinal hernia repair. *Surg Clin North Am*. 2008;88(5):1073-1081, vii-viii.
19. Ramshaw B, Abiad F, Voeller G, Wilson R, Mason E. Polyester (Parietex) mesh for total extraperitoneal laparoscopic inguinal hernia repair: initial experience in the United States. *Surg Endosc*. 2003;17(3):498-501.
20. Schwab JR, Beard DA, Ramshaw BJ, et al. After 10 years and 1903 inguinal hernias, what is the outcome for the laparoscopic repair? *Surg Endosc*. 2002;16(8):1201-1206.
21. Lal P, Kajla RK, Chander J, Saha R, Ramteke VK. Randomized controlled study of laparoscopic total extraperitoneal versus open Lichtenstein inguinal hernia repair. *Surg Endosc*. 2003;17(6):850-856.
22. Winslow ER, Quasebarth M, Brunt LM. Perioperative outcomes and complications of open vs laparoscopic extraperitoneal inguinal hernia repair in a mature surgical practice. *Surg Endosc*. 2004;18(2):221-227.
23. Koch CA, Greenlee SM, Larson DR, Harrington JR, Farley DR. Randomized prospective study of totally extraperitoneal inguinal hernia repair: fixation versus no fixation of mesh. *JSLs*. 2006;10(4):457-460.
24. Morrison JE Jr, Jacobs VR. Laparoscopic preperitoneal inguinal hernia repair using preformed polyester mesh without fixation: prospective study with 1-year follow-up results in a rural setting. *Surg Laparosc Endosc Percutan Tech*. 2008;18(1):33-39.
25. Lau H, Lee F. Seroma following endoscopic extraperitoneal inguinal hernioplasty. *Surg Endosc*. 2003;17(11):1773-1777.
26. Neumayer L, Giobbie-Hurder A, Jonasson O, et al; Veterans Affairs Cooperative Studies Program 456 Investigators. Open mesh versus laparoscopic mesh repair of inguinal hernia. *N Engl J Med*. 2004;350(18):1819-1827.
27. McCormack K, Wake B, Perez J, et al. Laparoscopic surgery for inguinal hernia repair: systematic review of effectiveness and economic evaluation. *Health Technol Assess*. 2005;9(14):1-203, iii-iv.

Call for Papers

Health Care Reform and Comparative Effectiveness: Implications for Surgeons

In 2010, we are soliciting manuscripts on the topic Health Care Reform and Comparative Effectiveness: Implications for Surgeons. The editorial board has selected this topic as our year-long theme. We are interested in papers that compare different interventions and strategies to treat surgical conditions. These interventions could be randomized, preferably prospective, and have adequate follow-up so that patients and other clinicians can use the information to make decisions on care. Registries, health data sets, and meta-analyses would be excellent sources for articles. Accepted manuscripts will be given priority publication. Please indicate in your cover letter that your manuscript is to be considered for this theme.

We have seen a change in the manuscripts submitted to *Archives* over the past year that has led to our increased impact factor as more surgeons and physicians cite our studies in their articles. Now we would like to increase our impact factor in patient care by publishing articles that focus on comparative effectiveness.