

Image of the Month

Vicky Ka Ming Li, MBBS, FRCS(Edin); Market Wai Chun Wong, MBChB, FRCS(Edin);
Patrick Ying Yu Lau, MBBS, FRCS(Edin)

OUR PATIENT WAS A 32-YEAR-OLD WOMAN who presented with fever and right lower quadrant pain. The clinical diagnosis was acute appendicitis. Diagnostic laparoscopy was performed. Reusable ports including an 11-mm subumbilical port, together with an 11-mm left lower quadrant port composed of HiCap trocar with multifunctional valve (Karl Storz, Tuttlingen, Germany) and a 5-mm suprapubic port, were respectively inserted for laparoscopy and working ports. Diagnosis of acute gangrenous appendicitis was confirmed, and appendicectomy was performed. Accidental diathermy injury was made at the terminal ileum, and serosal repair was performed with 3 0 polyglactin (31 mm, 1/2 C [circumference]) intracorporal interrupted stitches. The needle was inserted, and retrieval was attempted through the 11-mm

left lower quadrant port. The stitch was retrieved but the needle was missing. The inside lumen of the port was examined using the laparoscope, and the multifunctional valve was detached from the HiCap trocar for examination but failed to identify the needle. Thorough laparoscopy was then performed using a systemic approach with an additional 5-mm right lower quadrant port but identification of the needle was not possible. On-table abdominal x-ray was subsequently taken (**Figure 1**), and the 11-mm left lower quadrant port was removed, with the multifunctional valve again detached from the HiCap trocar for detailed reexamination under good lighting.

Where is the Needle?

- Inside the peritoneal cavity.
- Outside the operative table.
- Inside the multifunctional valve of the port.
- Inside the HiCap trocar of the port.

Author Affiliations: Department of Surgery, Kwong Wah Hospital, Kowloon, Hong Kong.

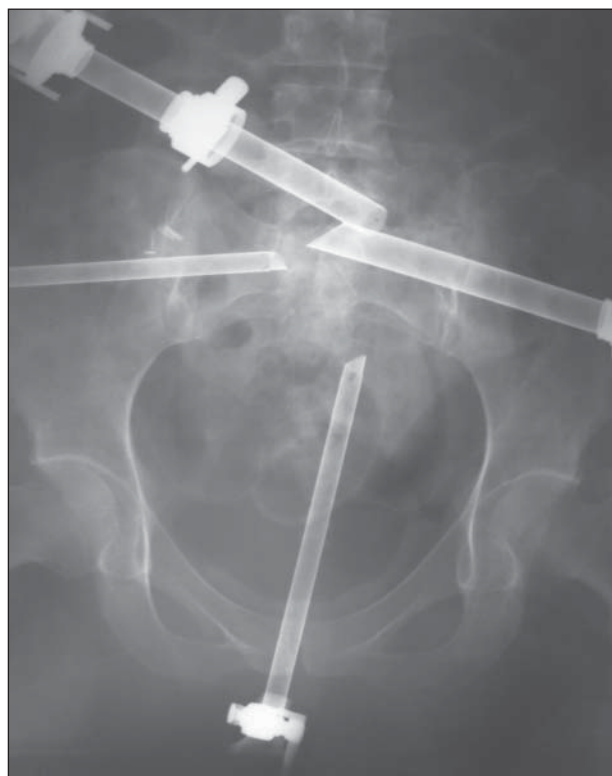


Figure 1. On-table wet film of the surgical field.

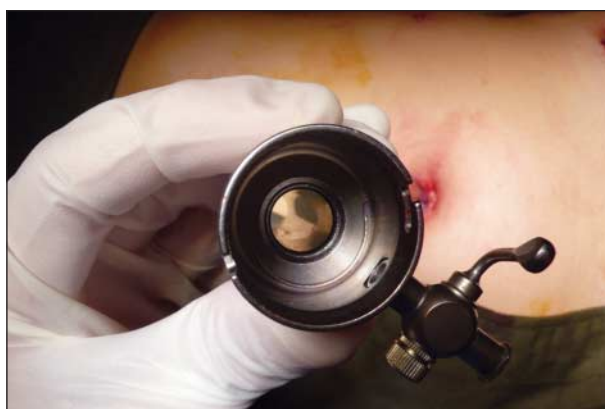

Figure 2. Inside view of the chamber of the HiCap trocar.