Image of the Month

Kensuke Adachi, MD, PhD; Kunio Takuma, MD; Kazuaki Enatsu, MD, PhD; Mitsugu Ishizawa, MD, PhD

A 33-YEAR-OLD MAN VISITED THE HOSPITAL with marked abdominal distention and vomiting. His medical history included epilepsy and mild mental retardation. He had no previous surgery or abdominal trauma history. Physical examination revealed a nontender, huge tumor palpable in the gross abdomen. Laboratory workup disclosed no abnormalities. An abdominal computed tomographic scan also showed a giant solid lesion occupying the entire abdominal cavity (**Figure 1**A). Angiography showed that the tumor was supplied by the bilateral internal iliac arteries, lumbar arteries, and branches of the superior and inferior mesenteric arteries (Figure 1B). Excisional biopsy under local anesthesia was carried out to confirm proliferation of spindle and epithelioid cells. Although the definitive diagnosis was uncertain at that time, exploratory laparotomy was carried out. He underwent en bloc tumor extirpation with resection of the sigmoid colon and distal ileum. The resected tumor was approximately 35 × 25 × 10 cm and weighed 4400 g. Pathological investigation revealed dense proliferation of spindle-shaped cells arranged in fascicles (**Figure 2**A). The immune profile of the tumor subsequently yielded positive expression of S-100 protein (Figure 2B), whereas there was negative staining of desmin.

Author Affiliations: Departments of Surgery (Drs Adachi and Takuma) and Pathology (Drs Enatsu and Ishizawa), Tokyo Metropolitan Tama Medical Center, Fuchu, Tokyo.

What Is the Diagnosis?

A. Ancient schwannoma
B. Malignant triton tumor
C. Malignant peripheral nerve sheath tumor
D. Epithelioid leiomyosarcoma

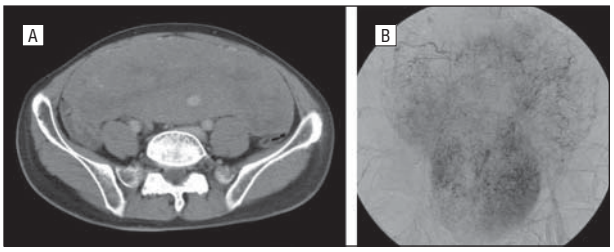

Figure 1. An abdominal computed tomographic scan showed a giant solid lesion occupying the entire abdominal cavity (A), and angiography showed a relatively hypervascular tumor in the entire abdomen (B).

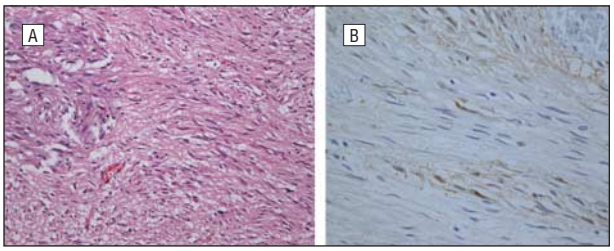

Figure 2. The tumor was composed of spindle-shaped cells arranged in fascicles (hematoxylin-eosin, original magnification ×20) (A), and immunohistochemical images showed positive staining of tumor cells for S-100 protein (anti–S-100 protein, original magnification ×40) (B).

©2013 American Medical Association. All rights reserved.

Downloaded From: http://archsurg.jamanetwork.com/ on 04/24/2017