

# Late Outcomes of Endovascular and Open Revascularization for Nonatherosclerotic Renal Artery Disease

Sung Wan Ham, MD; S. Ram Kumar, MD; Bonnie R. Wang, BA; Vincent L. Rowe, MD; Fred A. Weaver, MD, MMM

**Objective:** To evaluate the long-term outcome of endovascular and open treatment for nonatherosclerotic renal artery disease (NARAD).

**Design:** Retrospective review.

**Setting:** Academic institution.

**Patients:** Fifty-five patients (47 women; mean age, 40 years) with NARAD. Underlying disease included Takayasu arteritis in 31 and fibromuscular dysplasia in 24.

**Interventions:** Open revascularization and renal artery percutaneous transluminal angioplasty with or without stenting.

**Main Outcome Measures:** Primary, primary assisted, and secondary patency rates; blood pressure; antihypertensive medication requirements; renal function; and mortality.

**Results:** Seventy-nine renal interventions were performed, including 59 aortorenal bypass (16 *ex vivo*), 3 visceral-renal bypass, 12 endovascular (8 percutaneous transluminal angioplasty and 4 stent placements) procedures, and 5 nephrectomies. There were no in-hospital deaths. During a mean follow-up of 75 months,

1-, 3-, and 5-year primary patency rates for any intervention were 87%, 75%, and 75%, respectively; primary assisted/secondary patency rates were 92%, 86%, and 86%, respectively. Endovascular interventions at 1, 3, and 5 years had primary patency rates of 73%, 49%, and 49%, respectively, and primary assisted/secondary patency rates of 83%, 83%, and 83%, respectively. For open revascularization, 1-, 3-, and 5-year primary patency rates were 91%, 80%, and 80%, respectively; primary assisted/secondary patency rates were 94%, 87%, and 87%, respectively. For both interventions, blood pressure and the number of antihypertensives used were reduced compared with preintervention values (all  $P < .05$ ). Serum creatinine level and estimated glomerular filtration rate were also improved after revascularization (both  $P < .05$ ). There were 6 deaths. Five- and 10-year actuarial survival rates were 94% and 78%, respectively.

**Conclusions:** Endovascular and open management of NARAD confers long-term benefit for blood pressure, renal function, renal artery/graft patency, and survival. Open revascularization results in superior 1- and 5-year outcomes compared with endovascular management and provides the most durable outcome for NARAD.

*Arch Surg.* 2010;145(9):832-839

**Author Affiliations:** Division of Vascular Surgery and Endovascular Therapy, Keck School of Medicine, University of Southern California, Los Angeles.

**N**ONATHEROSCLEROTIC renal artery disease (NARAD), namely, fibromuscular dysplasia (FMD) and Takayasu arteritis (TA), accounts for a significant portion of correctable hypertension.<sup>1</sup> Fibromuscular dysplasia is a noninflammatory vascular disease that can affect almost any vascular bed but most commonly affects the renal arteries.<sup>2,3</sup> Fibromuscular dysplasia is characterized by hyperplastic and fibrotic lesions of the intima, media, and adventitia, giving rise to various subtypes classified by the artery wall involved. Approximately 85% of renal artery FMD lesions are of the medial fibroplasia subtype.<sup>4</sup> Fibromuscular dysplasia can also be associated with aneurysmal degeneration.<sup>5</sup>

Takayasu arteritis is a nonspecific granulomatous inflammatory aortitis of unknown etiology that affects the aorta and its major branches. It is an arteriopathy that leads to stenotic and occlusive disease and, less commonly, aneurysmal degeneration. Takayasu arteritis-induced renal artery stenosis can result in hypertension that is refractory to medication therapy, with subsequent renal and cardiac dysfunction leading to premature death.<sup>6-8</sup>

Although TA and FMD are pathologically different lesions, both may cause occlusive or aneurysmal disease of the renal arteries that leads to end organ dysfunction in the form of renovascular hypertension. It is well known that severe hypertension is an independent predictor of major adverse cardiac events and prema-

ture death in patients with NARAD.<sup>7,9,10</sup> Patients with TA and severe hypertension treated with pharmacologic therapy alone have a 5-year survival of less than 60%.<sup>9</sup> The value of surgical revascularization has been recognized for patients with TA; however, specific emphasis on TA-induced renal artery involvement and the long-term effects of renal revascularization are less well studied. On the other hand, renal revascularization in patients with FMD, including endovascular and surgical procedures, and their long-term outcomes are better established. However, longitudinal follow-up with consistent periodic imaging of the renal arteries or renal reconstruction is limited. In this report, an endovascular and surgical experience with NARAD is provided with a focus on the long-term durability of open and endovascular revascularization based on consistent, periodic longitudinal imaging and its effect on renal function, blood pressure (BP), and patient survival.

## METHODS

### PATIENT POPULATION

From 1977 through 2009, 55 patients underwent treatment for NARAD at the University of Southern California (USC) University Hospital or Los Angeles County + USC Medical Center. Hospital medical records, imaging studies, and outpatient records of patients with NARAD were reviewed with the approval of the USC Health Sciences institutional review board.

Nonatherosclerotic renal artery disease was identified in patients with TA and those with FMD. All patients with TA met diagnostic criteria according to the American College of Rheumatology.<sup>11</sup> The diagnosis of FMD was based on characteristic preoperative angiographic findings.

Collected data consisted of patient demographic, including race, age, and sex, and clinical data, including preoperative BP, history of previous vascular procedures, comorbidities, computed tomography and angiographic findings, procedures performed, associated 30-day/in-hospital morbidity and mortality, and late outcomes such as renal/graft patency by periodic duplex imaging and mortality. Hypertension was defined as systolic BP (SBP) of greater than 140 mm Hg or diastolic BP (DBP) of greater than 90 mm Hg<sup>12</sup> or preoperative use of at least 1 antihypertensive medication. Renal function was determined with serum creatinine (SCr) level, and estimated glomerular filtration rate (eGFR) was determined using the Cockcroft-Gault method.<sup>13</sup> Renal dysfunction was defined as an SCr level of 1.5 mg/dL or greater (to convert to micromoles per liter, multiply by 88.4) or the need for dialysis. The Social Security Death Index was used to investigate mortality for patients who were lost to follow-up.

Primary end points were comparison of preoperative BP, antihypertensive medication requirements, eGFR, and SCr level with those at follow-up; long-term patency rates of renal revascularization; and survival. Cure of hypertension was defined as a BP of less than 140/90 mm Hg and requiring no antihypertensive medications. Clinical improvement was defined as an SBP of less than 140 mm Hg or DBP of less than 90 mm Hg with the same number of antihypertensive medications or a reduction of DBP of at least 15 mm Hg with the same number of antihypertensive medications or fewer. Unchanged BP with a reduction in the number of antihypertensive medications was considered a clinical improvement. Response was considered to be not improved if the criteria for cure or for improvement were not fulfilled.

## IMAGING STUDIES

Preoperative aortography was performed on all patients before any surgical or endovascular intervention. Aortography included the abdominal aorta and selective bilateral renal artery angiograms for all patients. For patients with TA, aortography included the ascending aorta, aortic arch, and descending aorta to evaluate thoracic aortic involvement of disease. Computed tomography with intravenous contrast was performed to clarify the longitudinal extent of aortic/renal artery involvement and parenchymal asymmetry. Intraoperative duplex ultrasonography was routinely performed at the time of renal revascularization to assess the technical proficiency of all reconstructions. If abnormalities were detected, revision of the reconstruction was performed at the operating surgeon's discretion. Patency of renal revascularization was assessed by serial duplex ultrasonography at 1 and 6 months after the intervention, then annually thereafter. Computed tomographic angiography, magnetic resonance angiography, or aortography was used adjunctively as needed. Aortography was performed to confirm stenosis or occlusion when noninvasive imaging detected a renal artery restenosis or a graft stenosis or occlusion.

### ENDOASCULAR TECHNIQUE

Renal artery percutaneous transluminal angioplasty (PTA) and stenting were performed using femoral or left brachial access, with long 6F sheaths, 0.014/.018-inch-diameter wires and compatible balloons, and balloon expandable stents of 5 to 6 mm. Stenting was used selectively for elastic recoil with a greater than 30% residual stenosis or in the case of renal dissection. Technical success was defined by the elimination of preexisting pressure gradients across the stenosis and less than 30% residual stenosis on completion angiography.

### OPEN TECHNIQUE

Unilateral renal revascularization was achieved using a subcostal incision extended to the 12th rib for retroperitoneal exposure. For bilateral renal revascularizations, a midline transperitoneal approach was used. Operations were staged for bilateral revascularizations requiring ex vivo reconstruction. The preferred conduit was autogenous saphenous vein. Prosthetic or hypogastric artery was used when no suitable vein was available. Graft inflow was provided by a nondiseased segment of aorta. In select cases, when extensive aortic disease was present, splenic, hepatic, or common iliac arteries were used for inflow. The distal anastomosis was placed in the distal renal artery or branch points free of visible disease. When extensive branch disease was found, ex vivo techniques were used. In cases with inflammatory involvement of the entire renal artery or extension into the renal hilum where vascular reconstruction was not possible, nephrectomy was performed.

### STATISTICAL ANALYSIS

Continuous variables were summarized as mean (SE) and compared using 2-tailed *t* tests. Categorical variables were expressed as frequency and percentage. Renal revascularization patency rates and survival were estimated using the Kaplan-Meier method. Kaplan-Meier patency curves were compared using log-rank analysis. We considered *P* < .05 to be statistically significant. Statistical analysis was performed using commercially available software (SPSS, version 17.0; SPSS, Inc, Chicago, Illinois).

**Table 1. Demographic and Patient Characteristics<sup>a</sup>**

Characteristic	Patients With TA (n=31)	Patients With FMD (n=24)	All Patients (N=55)
Women	27 (87)	20 (83)	47 (85)
Age, mean (SE), y	33 (2.8)	49 (2.7)	40 (2.2)
Race			
Hispanic	20 (65)	6 (25)	26 (47)
White	4 (13)	14 (58)	18 (33)
Asian	7 (23)	3 (12)	10 (18)
Black	0	1 (4)	1 (2)
Hypertension	31 (100)	21 (88)	52 (95)
SBP, mean (SE), mm Hg	171 (6)	172 (5)	172 (3)
DBP, mean (SE), mm Hg	102 (4)	97 (3)	100 (3)
No. of antihypertensive medications, mean (SE)	2.4 (0.2)	2.3 (0.2)	2.3 (0.2)
Renal insufficiency <sup>b</sup>	7 (23)	1 (4)	8 (15)
Dialysis dependent	3 (10)	0	3 (5)
Baseline SCr level, mean (SE), mg/dL	1.2 (0.1)	0.8 (0.1)	1.1 (0.1)
Baseline eGFR, mean (SE), mL/min	77.8 (4.7)	103.8 (6.3)	88.9 (4.1)
Coronary artery disease	2 (6)	0	2 (4)
Congestive heart failure	2 (6)	0	2 (4)
Follow-up, mo			
Mean (SE)			75 (10)
Median (range)			62 (0.5-383.0)

Abbreviations: DBP, diastolic blood pressure; eGFR, estimated glomerular filtration rate; FMD, fibromuscular dysplasia; SCr, serum creatinine; SBP, systolic blood pressure; TA, Takayasu arteritis.

SI conversion factor: To convert SCr to micromoles per liter, multiply by 88.4.

<sup>a</sup>Unless otherwise indicated, data are expressed as number (percentage) of patients. Percentages have been rounded and may not total 100.

<sup>b</sup>Defined as an SCr level of 1.5 mg/dL or more and does not include dialysis-dependent patients. Data were not available for 3 patients.

## RESULTS

Fifty-five patients underwent 79 interventions for NARAD. Demographic data are summarized in **Table 1**. Mean age at the time of intervention was 40 (2.2) years. Forty-seven patients (85%) were women, and 26 (47%) were Hispanic. Eight patients had undergone previous renal interventions at outside hospitals, including 7 PTAs, 3 aortorenal bypasses, and 1 nephrectomy. All previous renal revascularizations had failed. Fourteen patients with TA (45%) were receiving corticosteroids or immunosuppressive medications at the time of renal revascularization.

At presentation, 52 patients (95%) had hypertension; the mean preintervention SBP for all patients with hypertension was 172 (3) mm Hg and the mean DBP was 100 (3) mm Hg while receiving a mean of 2.3 (0.2) antihypertensive medications. For all patients with TA, the mean SBP was 171 (6) mm Hg and the mean DBP was 102 (4) mm Hg while receiving 2.4 (0.2) medications. For patients with FMD, the mean SBP was 172 (5) and the mean DBP was 97 (3) mm Hg while receiving 2.3 (0.2) medications. Eleven patients (20%) had renal dysfunction. Ten of these patients (91%) had TA. Three of the 11 patients were dependent on dialysis. The mean SCr level was 1.1 (0.1) mg/dL and the mean eGFR was 88.9 (4.1) mL/min.

Seventy-four kidneys were successfully revascularized. Twelve kidneys in 9 patients (8 with FMD and 1 with

**Table 2. Number of Interventions<sup>a</sup>**

Intervention	No. of Interventions by Group		
	Patients With TA (n=31)	Patients With FMD (n=24)	All Patients (N=55)
PTA			
Balloon angioplasty	2	6	8
Stent	0	4	4
Surgery			
Aortorenal bypass	34	9	43
Aortorenal bypass with ex vivo repair	3	13	16
Visceral-renal bypass	3	0	3
Nephrectomy	5	0	5

Abbreviations: FMD, fibromuscular dysplasia; PTA, percutaneous transluminal angioplasty; TA, Takayasu arteritis.

<sup>a</sup>There were a total of 79 interventions in the 55 patients.

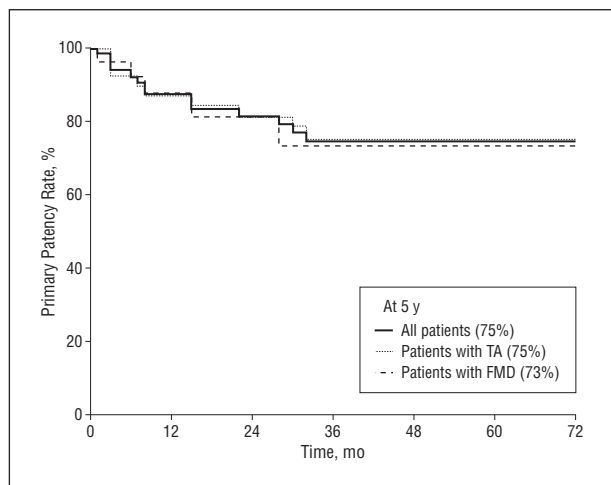
TA) were revascularized using PTA (n=8) or PTA with stent (n=4) (**Table 2**). Open revascularization was achieved using aortorenal bypass in 59 kidneys, of which 16 required ex vivo repair. Three kidneys were revascularized using splenic artery (n=2) and common hepatic artery (n=1) owing to extensive inflammatory TA of the abdominal aorta. Graft conduits for bypass included 43 saphenous veins, 17 prosthetic grafts, and 2 hypogastric arteries. Five nephrectomies were required, with 3 performed during contralateral revascularization, 1 before contralateral revascularization, and 1 as the sole procedure.

There were 8 major complications (10%) in 7 patients, including intra-abdominal bleeding requiring re-exploration (n=3), wound infection (n=2), myocardial infarction (n=1), mesenteric ischemia requiring superior mesenteric revascularization (n=1), and retroperitoneal hematoma after PTA with stent (n=1). There were no postoperative deaths.

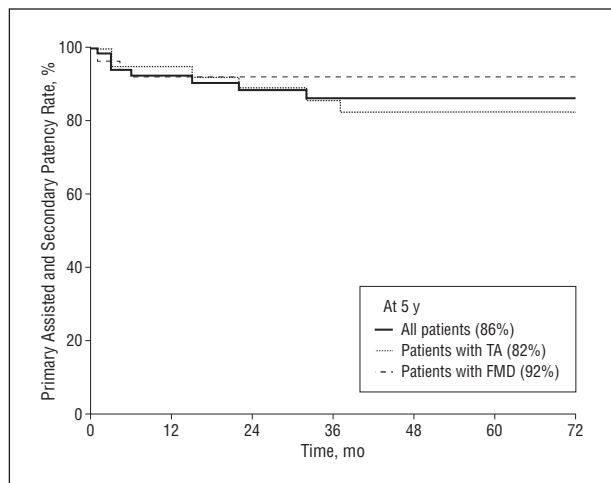
During a mean follow-up of 75 months (range, 0.5-383 months), 15 of 79 revascularizations (19%) failed in 13 patients (9 with TA and 4 with FMD). Ten renal/graft stenoses developed in 9 patients and 5 graft occlusions occurred in 4 patients. For all interventions, the primary patency rates at 1, 3, and 5 years were 87%, 75%, and 75%, respectively. Corresponding primary assisted and secondary patency rates were 92%, 86%, and 86%, respectively (**Figure 1** and **Figure 2**).

Five endovascular interventions developed restenosis in 4 patients with FMD within a median interval of 8 months (**Table 3**). Two patients underwent successful aortorenal bypass. One patient had bilateral renal artery restenosis and required a second PTA. The fourth patient developed restenosis at 28 months and underwent a second PTA with stent placement. Primary patency rates for endovascular procedures at 1, 3, and 5 years were 73%, 49%, and 49%, respectively. Corresponding primary assisted patency rates were 83%, 83%, and 83%, respectively (**Figure 3**).

Five bypass graft stenoses were detected at 3, 7, 8, 30, and 182 months (mean, 46 months). One patient underwent new graft placement, 1 had a graft revision, and



**Figure 1.** Kaplan-Meier analysis of primary patency rates for all interventions (endovascular and open bypass). One graft failure at 182 months is not shown. The standard error never exceeds 10% for all rates. FMD indicates fibromuscular dysplasia; TA, Takayasu arteritis.



**Figure 2.** Kaplan-Meier analysis of primary assisted and secondary patency rates for all interventions (endovascular and open bypass). One graft failure at 182 months is not shown. The standard error never exceeds 10% for all rates. FMD indicates fibromuscular dysplasia; TA, Takayasu arteritis.

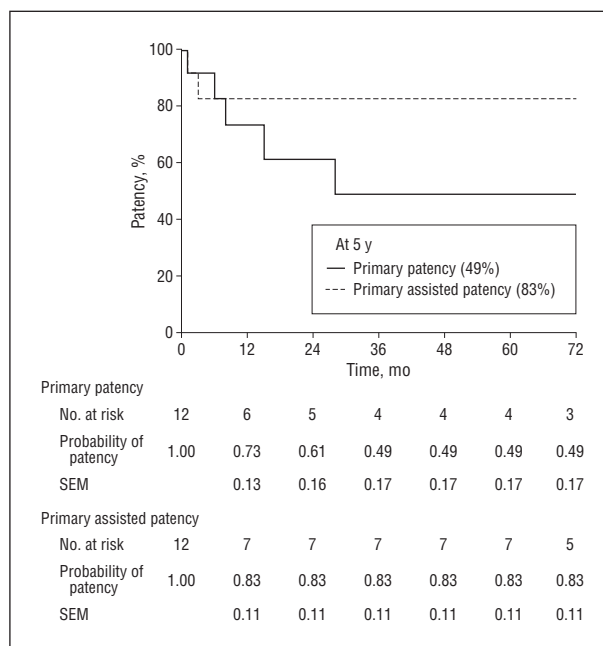
3 had renal/graft PTA. One patient required a second PTA for restenosis. Graft occlusions were documented in 4 patients with TA at 3, 3, 15, 22, and 32 months (mean, 15 months). One patient underwent a second revascularization with a splenorenal bypass. Another patient had significant inflammatory involvement of both renal arteries requiring branch vessel reconstruction. Revascularization was not attempted when bilateral grafts occluded. The remaining 2 patients underwent bilateral renal revascularization with subsequent occlusion of 1 bypass graft. At the last follow-up visit, both had a functioning contralateral kidney with a patent bypass graft (**Table 4**). Primary patency rates for open revascularization at 1, 3, and 5 years were 91%, 80%, and 80%, respectively, with corresponding primary assisted patency rates of 94%, 87%, and 87%, respectively (**Figure 4**). Five-year primary patency rates for all open revascularizations were significantly higher compared with those of endovascular interventions (**Figure 5**).

**Table 3. Treatment Failure in Patients Undergoing Primary Endovascular Procedures<sup>a</sup>**

Patient No./Sex/Age, y	Indication for Procedure	Procedure	Time to Restenosis, mo	Type of Reintervention
1/F/25	HTN	PTA, stent	1	Open bypass
2/F/37	HTN	PTA, stent	6	Open bypass
3/F/63	HTN	Left PTA	8	Second PTA
		Right PTA	15	Second PTA
4/F/54	HTN	PTA	28	Second PTA, stent

Abbreviations: HTN, hypertension; PTA, percutaneous transluminal angioplasty.

<sup>a</sup>Underlying disease in all 4 patients was fibromuscular dysplasia.



**Figure 3.** Kaplan-Meier analysis of primary and primary assisted patency rates for endovascular procedures only.

Mean SBP for all 52 hypertensive patients decreased to 132 (2) mm Hg and mean DBP decreased to 80 (2) mm Hg ( $P < .001$ ). The mean number of antihypertensive medications required was reduced to 1.3 (0.2) drugs per patient ( $P < .001$ ). Similarly, mean BP and antihypertensive medications required for the TA and FMD groups separately were significantly reduced (**Table 5**). Overall, 47 patients (90%) had a favorable BP response. Thirteen (25%) (12 with TA and 1 with FMD) were cured and 34 (65%) (17 with TA and 17 with FMD) improved, with treatment failure in 5 (10%) (2 with TA and 3 with FMD).

In the 49 patients who were not dependent on dialysis preoperatively, the SCr level decreased to 0.9 (0.1) mg/dL ( $P = .004$ ) and the eGFR improved to 99 (5) mL/min ( $P = .03$ ). Subgroup analysis showed positive changes in renal function for TA and FMD; however, the change was not statistically significant for patients with FMD. Two of 3 dialysis-dependent patients no longer required dialysis.



**Table 4. Treatment Failures in Patients Undergoing Open Revascularization Procedures<sup>a</sup>**

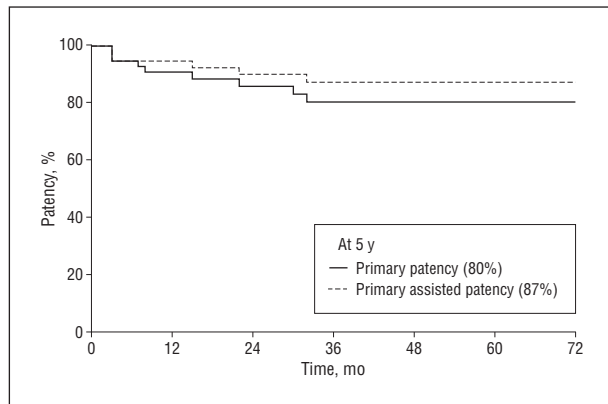
Patient No./Sex/ Age, y	Indication for Procedure	Procedure	Time to Failure, mo	Type of Reintervention
Restenosis				
1/F/34	HTN	Open bypass	3	Graft replacement
2/F/52	HTN	Open bypass	7	PTA
3/F/27	HTN	Open bypass	8	Graft revision
4/F/53	HTN	Open bypass	30	PTA
5/F/35	HTN	Open bypass	182	PTA, stent
Occlusion				
1/F/22	HTN	Right open bypass	3	None <sup>b</sup>
	Renal salvage	Left open bypass	3	None <sup>b</sup>
2/F/18		BL open bypass	15	None <sup>c</sup>
3/F/14		BL open bypass	22	None <sup>c</sup>
4/F/39		Open bypass	32	Splenorenal bypass

Abbreviations: BL, bilateral; HTN, hypertension; PTA, percutaneous transluminal angioplasty.

<sup>a</sup>Underlying disease in all 9 patients was Takayasu arteritis.

<sup>b</sup>Extensive disease of BL renal arteries required branch reconstruction; therefore, further revascularization was not attempted after BL graft occlusion.

<sup>c</sup>One graft occluded in each patient, with remaining patent contralateral bypass grafts and no significant change in blood pressure; therefore, no reintervention was pursued.

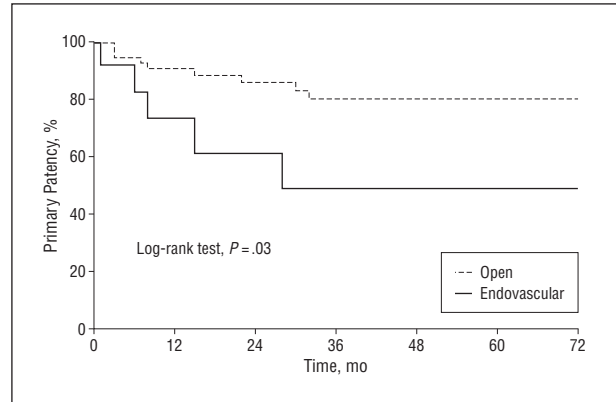


**Figure 4.** Kaplan-Meier analysis of primary and primary assisted patency rates for all surgical revascularization procedures only. One graft failure at 182 months is not shown. The standard error never exceeds 10% for all rates.

Six patients died during follow-up (5 with TA and 1 with FMD). One patient who underwent a successful revascularization died of a transfusion reaction 14 years after the initial procedure. Two patients with graft occlusion died, one of complications of renal failure and the other of a cardiac event. Four remaining patients who were lost to follow-up died of unknown causes. Five- and 10-year actuarial survival rates were 94% and 78%, respectively (**Figure 6**).

### COMMENT

Atherosclerosis accounts for approximately 70% of all renal artery disease<sup>14</sup> and is the focus of most reports concerning endovascular and open renal interventions. Con-



**Figure 5.** Comparison of primary patency rates between all open and all endovascular procedures using log-rank analysis.

**Table 5. Change in BP and Antihypertensive Medication Requirement<sup>a</sup>**

	Group		
	All Patients With HTN	Patients With TA and HTN	Patients With FMD and HTN
Preintervention			
SBP/DBP	172 (3)/100 (3)	171 (6)/102 (4)	172 (5)/97 (3)
Medications <sup>b</sup>	2.3 (0.2)	2.4 (0.2)	2.3 (0.2)
Postintervention			
SBP/DBP	132 (2)/80 (2)	131 (3)/79 (2)	134 (4)/82 (2)
Medications <sup>b</sup>	1.3 (0.2)	1.0 (0.2)	1.6 (0.2)

Abbreviations: BP, blood pressure; DBP, diastolic BP; FMD, fibromuscular dysplasia; HTN, hypertension; SBP, systolic BP; TA, Takayasu arteritis.

<sup>a</sup>Data are expressed as mean (SE). Differences between preintervention and postintervention blood pressure and use of medications were significant ( $P < .001$ ).

<sup>b</sup>Indicates number of antihypertensive medications used.

sequently, although NARAD accounts for a significant portion of correctable hypertension, it remains less well studied compared with its atherosclerotic counterpart.

Endovascular treatment as the primary modality in the management of NARAD is described more commonly for FMD than TA, with reported modest primary failure rates and limited long-term follow-up. Reported restenosis rates for FMD after PTA range from 7% to 34% during a follow-up of 6 to 24 months<sup>15-19</sup>; for patients with TA, these rates range from 14% to 21% during 8 to 22 months of follow-up.<sup>20-22</sup> In a series of 69 patients who underwent PTA for FMD, 34% of patients required at least 1 reintervention during 7 years, with most reinterventions occurring within the first 6 months.<sup>19</sup> Birrer et al<sup>23</sup> studied restenosis after PTA using serial duplex ultrasonography in 31 patients with 1-year follow-up. The restenosis rate was 23% at 12 months. In our study, we preferentially treated TA-associated renal artery stenosis with open surgical techniques, given the beneficial effects we previously reported for surgical revascularization in TA.<sup>24</sup>

In our series, 5 stenoses (50%) occurred in 4 patients in the first 28 months after PTA. All stenoses were detected on routine surveillance duplex ultrasonography and confirmed angiographically. Two patients with primary stent failures underwent successful open revascularization, and the remaining 3 underwent PTA, providing a pri-

primary assisted patency rate of 83% at 5 years. A recent study by Davies et al<sup>25</sup> reported similar findings in 29 patients with FMD and associated renovascular hypertension who were treated with primary endovascular therapy. The 5-year primary patency and primary assisted patency rates were 66% and 87%, respectively. Furthermore, 71% of patients maintained a cure or improvement in hypertension at 5 years. These reports and our experience suggest that restenosis after PTA for NARAD occurs in roughly one-third of patients. However, repeated endovascular intervention in these patients appears to be effective in providing acceptable primary assisted patency rates and associated BP improvement.<sup>25,26</sup>

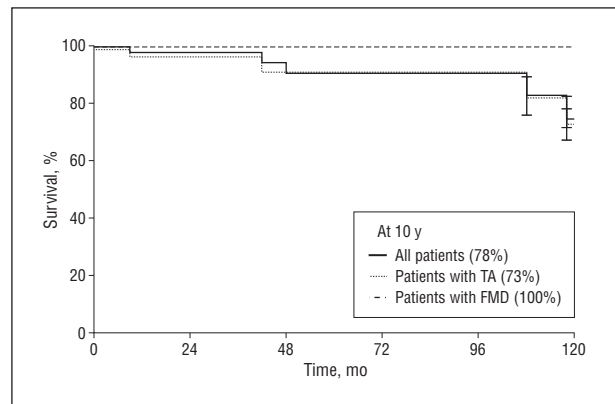
Our positive results and those of Davies et al<sup>25</sup> are predicated at least in part on consistent longitudinal imaging with duplex ultrasonography. Nonetheless, few studies report routine surveillance imaging of renovascular interventions for FMD or TA, relying instead on clinical variables such as poorly controlled BP or declining renal function as triggers to perform imaging studies. The value of clinical follow-up as a surrogate marker for restenosis has been questioned by many authors who have demonstrated a discrepancy between clinical response and anatomic results.<sup>27</sup>

A previous report from our group<sup>28</sup> in patients with TA documented the safety and benefit of open revascularization. Other groups have reported salutary outcomes after open revascularization in patients with NARAD. Carmo et al<sup>29</sup> reported a series of 26 patients with FMD who underwent 32 renal artery revascularizations with 1 graft stenosis and 2 occlusions, resulting in a primary patency rate of 89% at 1 year. Moreover, Alhadad et al<sup>19</sup> reported no need for reintervention in 8 patients with FMD who underwent surgical renal revascularization during a 7-year follow-up.

Our present study further confirms the durability of open revascularization in patients with NARAD. A total of 62 open revascularizations were performed, after which 5 graft stenoses and 5 graft occlusions were detected during a mean follow-up of 75 months. Detection of graft stenosis before the occurrence of graft occlusion allowed successful PTA or graft revision in all 5 stenotic grafts, providing a patency rate of 87% at 5 years. This illustrates how the results of open revascularization can be optimized by using consistent longitudinal surveillance imaging. Detection of graft stenosis before graft occlusion facilitates revision and in selected patients allows for a percutaneous solution.

Overall, superior primary patency rates were associated with open renal revascularization when compared with endovascular management. This was despite the fact that in general open revascularization was selected for patients with more extensive and complicated renal artery disease, as evidenced by the 16 *ex vivo* repairs. Our experience and that of others suggest that in general superior patency rates follow open revascularization for NARAD.

Reported rates of cure and improvement of hypertension after PTA for FMD range from 14% to 57% and 21% to 63%, respectively.<sup>30-32</sup> Davies et al<sup>25</sup> reported a combined cure/improvement rate of 72% at 1 year. Similarly, in our cohort, 75% of patients treated with PTA ex-



**Figure 6.** Kaplan-Meier analysis of survival for all patients. Vertical bars represent standard error of greater than 10%. The standard error for all other rates is less than 10%. Two deaths are not shown at 160 and 170 months. FMD indicates fibromuscular dysplasia; TA, Takayasu arteritis.

perienced cure or improvement in BP during the follow-up period.

Reported cure and improvement rates for FMD after open revascularization are 33% to 63% and 24% to 57%, respectively, and in general are superior to those reported for PTA.<sup>33-36</sup> Of all patients treated with open revascularization in our study, 25% were cured whereas 65% improved. Similarly, Carmo et al<sup>29</sup> reported cure and improvement rates of 27% and 60%, respectively, in patients treated surgically for FMD-induced renovascular hypertension. The benefits on BP after open revascularization generally correlate well with technical outcome as measured by graft patency rates in our study as well as in others.<sup>29,33-36</sup>

Overall, there was a significant reduction in SCr level and improvement in eGFR from baseline. Subgroup analysis showed statistically significant improvement in renal function for patients with TA, which was consistent with our previous experience.<sup>28</sup> However, the improvement seen in FMD was not statistically significant, likely because only 1 patient had renal dysfunction at baseline.

The minimal in-hospital morbidity and absence of mortality in this study are indicative of the relative youth and absence of comorbidities in patients with NARAD. Other studies have reported similar low rates of mortality and morbidity. In a series of 101 patients with FMD treated with open revascularization, 30-day mortality was 2%.<sup>35</sup> Mwipatayi et al<sup>37</sup> reported their experience in South Africa with 115 patients who had TA and who underwent surgical revascularization for various aortic and aortic main branch disease. Operative mortality was 4%. These low mortality rates for open revascularization in patients with NARAD are in contrast to atherosclerosis, in which patients are generally older and have multiple comorbidities. A recent report from the National Inpatient Sample documented an operative mortality rate of 10% for open renal revascularization in patients with atherosclerotic renal artery disease.<sup>38</sup>

The role of endovascular and open renal revascularization in extending the lives of patients with NARAD is evident in this report. With a mean follow-up of more than 6 years, the 5- and 10-year actuarial survival rates

were 94% and 78%, respectively. A report from Japan documented a 20-year survival of 73% in 36 patients with TA who underwent surgical treatment for renovascular hypertension.<sup>39</sup> This is in contrast to a documented decrease in survival among patients with TA in whom, in the absence of open revascularization of renal artery disease and associated hypertension, premature death from cardiovascular causes has been documented.<sup>9</sup>

Currently, it is generally agreed that, in patients with NARAD associated with severe hypertension, endovascular or open renal revascularization is superior to medical management alone. Percutaneous transluminal angioplasty is considered the first line of therapy for FMD, and some have argued for a similar approach to TA.<sup>20-22</sup> The ease of endovascular intervention and patient comfort make this an attractive choice for the primary intervention. However, this recommendation should be considered in the context that most patients with NARAD are relatively young compared with their atherosclerotic counterparts. Durability and associated long-term benefit in controlling the hypertensive diathesis is a critical consideration when deciding on the best renal intervention for a given patient. In this context, the more complex involvement (ie, branch disease, aneurysm) and the younger the patient with NARAD, the more likely open revascularization will provide the most durable long-term result.

In conclusion, TA and FMD are 2 forms of NARAD that, although they differ in etiology, contribute to end organ dysfunction and to hypertension that is poorly controlled by medication alone. Both endovascular and open revascularization were found to be safe, durable, and effective in the management of renal artery-mediated hypertension and renal dysfunction. After either intervention, the late results are enhanced by consistent surveillance imaging, which is critical to early detection of renal or graft stenosis before occlusion. Finally, primary open revascularization provides a superior outcome with respect to patency and equivalent safety compared with endovascular intervention. Open revascularization should be considered selectively as the first line of therapy for NARAD, particularly in the young patient with moderate to complex renal artery disease.

**Accepted for Publication:** May 6, 2010.

**Correspondence:** Fred A. Weaver, MD, MMM, Division of Vascular Surgery and Endovascular Therapy, Keck School of Medicine, University of Southern California, 1520 S San Pablo St, Ste 4300, Los Angeles, CA 90033 (fweaver@surgey.usc.edu).

**Author Contributions:** *Study concept and design:* Ham and Weaver. *Acquisition of data:* Ham, Kumar, Wang, and Rowe. *Analysis and interpretation of data:* Ham, Kumar, and Weaver. *Drafting of the manuscript:* Ham and Weaver. *Critical revision of the manuscript for important intellectual content:* Ham, Kumar, Wang, Rowe, and Weaver. *Statistical analysis:* Ham and Kumar. *Administrative, technical, and material support:* Ham, Wang, and Weaver. *Study supervision:* Ham and Weaver.

**Financial Disclosure:** None reported.

**Previous Presentation:** This paper was presented at the

81st Annual Meeting of the Pacific Coast Surgical Association; February 15, 2010; Kapalua, Hawaii; and is published after peer review and revision.

## REFERENCES

- Weaver FA, Kuehne JP, Papanicolaou G. A recent institutional experience with renovascular hypertension. *Am Surg.* 1996;62(3):241-245.
- Harrison EG Jr, McCormack LJ. Pathologic classification of renal arterial disease in renovascular hypertension. *Mayo Clin Proc.* 1971;46(3):161-167.
- Stanley JC, Gewertz BL, Bove EL, Sottuirai V, Fry WJ. Arterial fibrodysplasia. Histopathologic character and current etiologic concepts. *Arch Surg.* 1975;110(5):561-566.
- Plouin PF, Perdu J, La Batide-Alanore A, Boutouyrie P, Gimenez-Roqueplo AP, Jeunemaitre X. Fibromuscular dysplasia. *Orphanet J Rare Dis.* 2007;2:28. doi:10.1186/1750-1172-2-28.
- Torres G, Terramani TT, Weaver FA. Ex vivo repair of a large renal artery aneurysm and associated arteriovenous fistula. *Ann Vasc Surg.* 2002;16(2):141-144.
- Numano F, Kobayashi Y. Takayasu arteritis: beyond pulselessness. *Intern Med.* 1999;38(3):226-232.
- Sharma BK, Jain S, Radotra BD. An autopsy study of Takayasu arteritis in India. *Int J Cardiol.* 1998;66(suppl 1):S85-S91.
- Koide K. Takayasu arteritis in Japan. *Heart Vessels Suppl.* 1992;7:48-54.
- Kumar R, Joy J, Balakrishnan KG. Natural history of aortoarteritis (Takayasu's disease). *Circulation.* 1989;80(3):429-437.
- Ishikawa K. Survival and morbidity after diagnosis of occlusive thromboangiopathy (Takayasu's disease). *Am J Cardiol.* 1981;47(5):1026-1032.
- Arend WP, Michel BA, Bloch DA, et al. The American College of Rheumatology 1990 criteria for the classification of Takayasu arteritis. *Arthritis Rheum.* 1990;33(8):1129-1134.
- Chobanian AV, Bakris GL, Black HR, et al; National Heart, Lung, and Blood Institute Joint National Committee on Prevention, Detection, Evaluation, and Treatment of High Blood Pressure; National High Blood Pressure Education Program Coordinating Committee. The Seventh Report of the Joint National Committee on Prevention, Detection, Evaluation, and Treatment of High Blood Pressure: the JNC 7 report. *JAMA.* 2003;289(19):2560-2572.
- Cockcroft DW, Gault MH. Prediction of creatinine clearance from serum creatinine. *Nephron.* 1976;16(1):31-41.
- Darling RC III, Kreienberg PB, Chang BB, et al. Outcome of renal artery reconstruction: analysis of 687 procedures. *Ann Surg.* 1999;230(4):524-532.
- Jensen G, Zachrisson BF, Delin K, Volkman R, Aurell M. Treatment of renovascular hypertension: one year results of renal angioplasty. *Kidney Int.* 1995;48(6):1936-1945.
- Klow NE, Paulsen D, Vatne K, Rokstad B, Lien B, Fauchald P. Percutaneous transluminal renal artery angioplasty using the coaxial technique: ten years of experience from 591 procedures in 419 patients. *Acta Radiol.* 1998;39(6):594-603.
- Plouin PF, Darné B, Chatellier G, et al. Restenosis after a first percutaneous transluminal renal angioplasty. *Hypertension.* 1993;21(1):89-96.
- Baumgartner I, Triller J, Mahler F. Patency of percutaneous transluminal renal angioplasty: a prospective sonographic study. *Kidney Int.* 1997;51(3):798-803.
- Alhadad A, Mattiasson I, Ivancev K, Gottsäter A, Lindblad B. Revascularisation of renal artery stenosis caused by fibromuscular dysplasia: effects on blood pressure during 7-year follow-up are influenced by duration of hypertension and branch artery stenosis. *J Hum Hypertens.* 2005;19(10):761-767.
- Sharma S, Saxena A, Talwar KK, Kaul U, Mehta SN, Rajani M. Renal artery stenosis caused by nonspecific arteritis (Takayasu disease): results of treatment with percutaneous transluminal angioplasty. *AJR Am J Roentgenol.* 1992;158(2):417-422.
- Sharma S, Gupta H, Saxena A, et al. Results of renal angioplasty in nonspecific aortoarteritis (Takayasu disease). *J Vasc Interv Radiol.* 1998;9(3):429-435.
- Tyagi S, Singh B, Kaul UA, Sethi KK, Arora R, Khalilullah M. Balloon angioplasty for renovascular hypertension in Takayasu's arteritis. *Am Heart J.* 1993;125(5, pt 1):1386-1393.
- Birrer M, Do DD, Mahler F, Triller J, Baumgartner I. Treatment of renal artery fibromuscular dysplasia with balloon angioplasty: a prospective follow-up study. *Eur J Vasc Endovasc Surg.* 2002;23(2):146-152.
- Weaver FA, Yellin AE, Campen DH, et al. Surgical procedures in the management of Takayasu's arteritis. *J Vasc Surg.* 1990;12(4):429-439.
- Davies MG, Saad WE, Peden EK, Mohiuddin IT, Naoum JJ, Lumsden AB. The long-term outcomes of percutaneous therapy for renal artery fibromuscular dysplasia. *J Vasc Surg.* 2008;48(4):865-871.
- Kim HJ, Do YS, Shin SW, et al. Percutaneous transluminal angioplasty of renal

- artery fibromuscular dysplasia: mid-term results. *Korean J Radiol.* 2008;9(1):38-44.
27. Oertle M, Do DD, Baumgartner I, Triller J, Mahler F. Discrepancy of clinical and angiographic results in the follow-up of percutaneous transluminal renal angioplasty (PTRA). *Vasa.* 1998;27(3):154-157.
  28. Weaver FA, Kumar SR, Yellin AE, et al. Renal revascularization in Takayasu arteritis-induced renal artery stenosis. *J Vasc Surg.* 2004;39(4):749-757.
  29. Carmo M, Bower TC, Mozes G, et al. Surgical management of renal fibromuscular dysplasia: challenges in the endovascular era. *Ann Vasc Surg.* 2005;19(2):208-217.
  30. Baert AL, Wilms G, Amery A, Vermeylen J, Suy R. Percutaneous transluminal renal angioplasty: initial results and long-term follow-up in 202 patients. *Cardiovasc Intervent Radiol.* 1990;13(1):22-28.
  31. de Fraissinette B, Garcier JM, Dieu V, et al. Percutaneous transluminal angioplasty of dysplastic stenoses of the renal artery: results on 70 adults. *Cardiovasc Intervent Radiol.* 2003;26(1):46-51.
  32. Bonelli FS, McKusick MA, Textor SC, et al. Renal artery angioplasty: technical results and clinical outcome in 320 patients. *Mayo Clin Proc.* 1995;70(11):1041-1052.
  33. Marekovic Z, Mokos I, Krhen I, Goreta NR, Roncevic T. Long-term outcome after surgical kidney revascularization for fibromuscular dysplasia and atherosclerotic renal artery stenosis. *J Urol.* 2004;171(3):1043-1045.
  34. Anderson CA, Hansen KJ, Benjamin ME, Keith DR, Craven TE, Dean RH. Renal artery fibromuscular dysplasia: results of current surgical therapy. *J Vasc Surg.* 1995;22(3):207-216.
  35. Reiher L, Pfeiffer T, Sandmann W. Long-term results after surgical reconstruction for renal artery fibromuscular dysplasia. *Eur J Vasc Endovasc Surg.* 2000;20(6):556-559.
  36. Novick AC, Ziegelbaum M, Vidt DG, Gifford RW Jr, Pohl MA, Goormastic M. Trends in surgical revascularization for renal artery disease: ten years' experience. *JAMA.* 1987;257(4):498-501.
  37. Mwipatayi BP, Jeffery PC, Beningfield SJ, et al. Takayasu arteritis: clinical features and management: report of 272 cases. *ANZ J Surg.* 2005;75(3):110-117.
  38. Modrall JG, Rosero EB, Smith ST, et al. Operative mortality for renal artery bypass in the United States: results from the National Inpatient Sample. *J Vasc Surg.* 2008;48(2):317-322.
  39. Miyata T, Sato O, Koyama H, Shigematsu H, Tada Y. Long-term survival after surgical treatment of patients with Takayasu's arteritis. *Circulation.* 2003;108(12):1474-1480.