

## Image of the Month

Antonio D. Lassaletta, MD; Frankie B. Fike, MD; Ketan R. Sheth, MD

**A** 61-YEAR-OLD MAN, WHO WAS A RECENT IMMIGRANT from rural India and a lifelong strict vegetarian, presented to the emergency department complaining of 2 days of diffuse and progressive abdominal pain that did not improve with 400 mg of ibuprofen. Through an interpreter, he reported having had no episodes of emesis and no changes in bowel movements, the last one of which occurred the morning of presentation. His last oral intake, which was also the morning of presentation, consisted of tea and was well tolerated despite worsening abdominal pain. He reported no recent changes in dietary patterns. His medical history was significant only for migraines, for which he took imipramine and carbamazepine.

On physical examination, the patient was alert but in obvious discomfort, had a temperature of 38.4°C (101.2°F), and was tachycardic at 132 beats per minute in sinus rhythm with a blood pressure of 132/78 mm Hg. His abdomen was distended and diffusely tender, although more tender in the left upper and lower quadrants where guarding was noted with palpation but without rebound tenderness. Blood tests revealed a white blood cell count of 9000/ $\mu\text{L}$  (to convert to  $\times 10^9$  per liter, multiply by 0.001), consisting of 77% segmented neutrophils and 12% band neutrophils, and a hematocrit of 43%

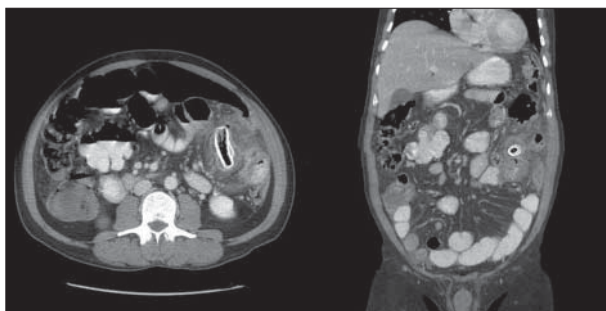
**Author Affiliations:** Department of Surgery, Cambridge Hospital (Drs Lassaletta, Fike, and Sheth), and Harvard Medical School, Harvard University (Drs Lassaletta, Fike, and Sheth), and Department of Surgery, Beth Israel Deaconess Medical Center (Drs Lassaletta and Fike), Boston, Massachusetts.

(to convert these 3 percentages to proportion of 1.0, multiply by 0.01). Guaiac testing of stool specimen obtained from the patient revealed occult blood.

Imaging obtained in the emergency department included plain films of the abdomen showing scattered, mildly dilated loops of small bowel with associated air-fluid levels, as well as a tubular abdominal calcification on the left side. Computed tomography of the abdomen using oral and intravenous contrast agents revealed a 10-cm left-sided, midabdomen phlegmon with what appeared to be a 5  $\times$  1.8-cm corticated bone or bone fragment (**Figure 1**). The phlegmon was associated with a small-bowel obstruction. There was free fluid in the pelvis but no free air. After questioning specifically about the possibility of an impacted bone, the patient vehemently reaffirmed his vegetarianism. However, his physical examination findings and computed tomographic images were concerning for small bowel-obstruction with perforation. The patient was taken urgently to the operating room whereupon entering the peritoneum, turbid fluid was encountered.

### What Is the Diagnosis?

- A. Impacted bone fragment with small-bowel perforation
- B. Perforated small-bowel diverticulum with calcified fecalith
- C. Perforated left-colon diverticulitis with associated phlegmon causing small-bowel obstruction
- D. Ruptured mesenteric calcified echinococcal cyst



**Figure 1.** Computed tomographic images showing a 5  $\times$  1.8-cm calcification on the left side of the midabdomen with an associated 10-cm phlegmon.