

## Brief Report | RESIDENT'S FORUM


# Preoperative Superselective Mesenteric Angiography and Methylene Blue Injection for Localization of Obscure Gastrointestinal Bleeding

Madhava Pai, MS, FRCS; Adam E. Frampton, MSc, MRCS; Jagdeep S. Virk, MRCS; Nyooti Nehru, MBBS; Charis Kyriakides, MD; Paolo Limongelli, MD; James E. Jackson, FRCR; Long R. Jiao, MD, FRCS

Localizing obscure gastrointestinal bleeding can be a clinical challenge, despite the availability of various endoscopic, imaging, and visceral angiographic techniques. We reviewed the management of patients presenting with obscure gastrointestinal bleeding during the period from 2005 to 2011. Four patients had preoperative localization of the bleeding site with superselective mesenteric angiography, which was confirmed by the use of intraoperative methylene blue injection. This novel technique allowed us to identify the abnormal pathology, and, consequently, resection of the implicated segment of small bowel was performed without any postoperative complications. Final histology showed that 2 patients had arteriovenous malformations: one had a benign hemangioma of the small bowel, and the other had chronic ischemic ulceration in the ileum. Superselective mesenteric angiography combined with intraoperative localization with methylene blue is an important and innovative technique in the management of patients with unclear sources of gastrointestinal bleeding and allows for effective hemorrhage control with a focused and therefore limited bowel resection.

*JAMA Surg.* 2013;148(7):665-668. doi:10.1001/jamasurg.2013.345  
Published online May 29, 2013.

 Video at [jamasurgery.com](http://jamasurgery.com)

 Supplemental content at [jamasurgery.com](http://jamasurgery.com)

**Author Affiliations:** Author affiliations are listed at the end of this article.

**Corresponding Author:** Long R. Jiao, MD, FRCS, Hepatopancreaticobiliary Surgical Unit, Department of Surgery and Cancer, Imperial College, Hammersmith Hospital campus, Du Cane Road, London W12 0HS, England ([l.jiao@imperial.ac.uk](mailto:l.jiao@imperial.ac.uk)).

**Section Editors:** Richard D. Schulick, MD, MBA; Pamela A. Lipsett, MD, MPHE.

Despite a wide range of investigational techniques to aid localizing sites of gastrointestinal (GI) bleeding, approximately 5% of patients continue to bleed from an unidentified source.<sup>1,2</sup> In these cases, the small bowel usually becomes the focus of inquiry when the site of bleeding is not apparent following standard investigations. Obscure GI bleeding (OGIB) has been reported to be of small-bowel origin in 45% to 75% of patients.<sup>2-5</sup> We describe 4 patients with OGIB who had preoperative localization of small-bowel bleeding sites using superselective mesenteric angiography (SSMA) and intraoperative methylene blue injection.

## Methods

Of the emergency patients referred for OGIB, 4 were managed in our surgical department with this novel technique because the standard investigations failed to reveal the source of hemorrhage, and the transfusion requirements continued. All patients had an upper and lower GI endoscopy, followed by a capsule endoscopy. In addition, 2 patients had a push enteroscopy. Because the source of bleeding was not identified using these procedures, a multidisciplinary decision for SSMA followed by surgery was made after a discussion between the gastroenterologist, the interventional radiologist, and the surgeon. All patients were prepared to go straight to the operat-

ing room after undergoing visceral angiography. A superior mesenteric angiogram was performed in the standard fashion via the femoral artery route. Following localization of the abnormality, a guide wire was passed, and a 3F highly selective catheter was passed in the distal arterial branch over the guide wire. The catheter was secured and left indwelling, while the patient was transferred to the operating room. One senior surgeon (L.R.J.) performed all of the procedures. At exploratory laparotomy, 0.5 mL of methylene blue dye (10 mg/mL) was injected into the catheter, which resulted in immediate demarcation of the small intestine over a length of about 20 cm with brilliant blue color (Video). The delineated segment of bowel was resected in each patient with adequate margins, followed by primary anastomosis.

## Results

Patient characteristics and outcomes can be seen in our Table. For patients with an active OGIB detected on a visceral angiographic scan, the SSMA technique had a 100% success rate. During this period, a total of 6 patients underwent visceral angiography, and of these 6 patients, 3 had active bleeding; therefore, SSMA was performed. The other 3 patients had no initial active extravasation and did not need subsequent intervention because their bleeding stopped spontaneously.

However, 1 patient rebled and had to undergo an SSMA following another visceral angiography that detected OGIB (Figure). Intraoperatively, there were no palpable lesions found in 3 patients, while 1 patient had a small nodule in the ileum that could have been easily overlooked. Three patients underwent a resection of the ileum, and 1 patient underwent a segmental resection of the jejunum. The

median length of resection was 10 cm (range, 9-12 cm). Final histology showed arteriovenous malformations in 2 patients, a benign hemangioma in 1 patient, and a nonspecific chronic ischemic ulceration in 1 patient. All patients had an uneventful postoperative recovery. At median follow-up of 18 months (range, 10-24 months), no patients experienced rebleeding.

Table. Clinical Characteristics and Outcomes of Patients Undergoing SSMA

Patient No./Sex/ Age, y	Presenta- tion	Investigations Performed	Trends in Hb, <sup>a</sup> g/dL	Time		Blood Products, <sup>b</sup>	Operative Finding	Surgical Resection	Histology	Time in OR, h	Complications	LOS, <sup>c</sup> d	Outcome <sup>d</sup>
				From Presen- tation to SSMA, d	In Angiog- raphy Suite, h								
1/F/53	Melena, anemia	EGD, colonoscopy, CE, PE, angiography	6.7, 8.0, 10.4	10	2.5	12, 2	No palpable lesion	Ileum (10 cm)	AVM	3	None	7	No rebleeding at 24 mo
2/M/74	Melena, anemia	EGD, colonoscopy, CE, angiography	8.2, 7.6, 11.5	8	2	8, 0	No palpable lesion	Jejunum (10 cm)	AVM	2.5	Postoperative ileus	12	No rebleeding at 18 mo
3/F/55	Rectal bleeding	EGD, colonoscopy, CE, PE, angiography	5.8, 7.4, 10.9	12	3	18, 3	No palpable lesion	Ileum (12 cm)	Benign hemangioma	2.5	Thrombophlebitis	9	No rebleeding at 18 mo
4/M/53	Anemia	EGD, CE, angiography	7.2, 7.8, 11.6	6	2	9, 0	Small nodule	Ileum (9 cm)	Chronic ischemic ulceration	3.5	None	9	No rebleeding at 10 mo

Abbreviations: AVM, arteriovenous malformation; CE, capsule endoscopy; EGD, esophagogastroduodenoscopy; Hb, hemoglobin; LOS, length of hospital stay; OR, operating room; PE, push enteroscopy; SSMA, superselective mesenteric angiography.

SI conversion factor: To convert Hb to grams per liter, multiply by 10.

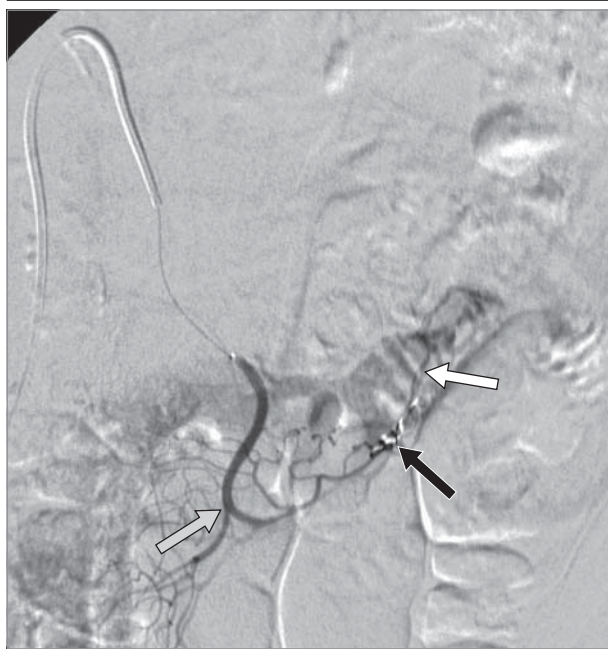<sup>a</sup> For each patient, the 3 values represent the Hb level at day of hospital admission, day of SSMA and surgery, and day of hospital discharge, respectively.

<sup>b</sup> For each patient, the 2 values represent red blood cells and fresh frozen plasma, respectively.

<sup>c</sup> After SSMA and surgery.

<sup>d</sup> Rebleeding was defined as further evidence of gastrointestinal hemorrhage in the form of melena, rectal bleeding, or unexplained anemia.

Figure. Superselective Mesenteric Angiography, Which Localizes a Vascular Abnormality in the Small Bowel



A patient with an actively bleeding arteriovenous malformation in the jejunum, despite attempted embolization, underwent SSMA and catheter localization prior to exploration in the operating room. Visceral angiography was performed via a right femoral artery puncture using a 7F sheath and catheter and a 3F coaxial catheter. A contrast agent (Ultravist 300; Bayer) was injected into the inferior mesenteric artery, the superior mesenteric artery, and the fifth and sixth jejunal arteries to delineate the pathology. The patient was found to have arteriosclerotic vessels and no signs of active extravasation. The site of previous embolization in the territory of the sixth jejunal artery can be seen (black arrow), as well as a small vessel bypassing the embolized segment (white arrow) to supply an abnormal-looking area of jejunum containing prominent vascular spaces and early venous drainage. These appearances were consistent with revascularization of the previously embolized arteriovenous malformation. The abnormality was situated at the junction of the territory supplied by the fifth and sixth jejunal arteries. The coaxial catheter was left in the sixth jejunal artery (gray arrow), and the patient was transferred to the operating room for laparotomy and resection following methylene blue injection.

## Discussion

Although uncommon, the management of OGIB can often be difficult and frustrating, especially if the bleeding originates from the small bowel. Angiodysplasia is the most common cause of acute or chronic hemorrhage from the small bowel,<sup>6,7</sup> and these lesions are difficult to diagnose and locate during laparotomy.<sup>8</sup> When patients present with exsanguinating GI bleeding, emergency surgery may be the only lifesaving possibility, after all nonoperative interventions have been tried (eTable in Supplement). Intraoperatively, lesions may be identified by visual inspection, illumination, or palpation. However, up to 50% of small-bowel lesions can be missed during laparotomy.<sup>9</sup> An aggressive approach to preoperative localization of the bleeding source may prevent the high morbidity and mortality rates of blind surgical resection performed in desperation.<sup>10</sup> Indeed, the lowest rebleeding rates after bowel resection for angiodysplasia have been reported in these situations.<sup>11-13</sup> Fogler et al<sup>14</sup> first supported the injection of methylene blue through a catheter placed in the superior mesenteric artery during laparotomy and localized a jejunal arteriovenous malformation on the basis of more rapid clearance of the dye from the lesion. This method had a distinct disadvantage in that an extensive dissection of the superior mesenteric artery was required. Improving on that, Athanasoulis and colleagues<sup>15</sup> described an intraoperative localization procedure by injecting methylene blue through a superselective prepositioned angiographic catheter. This typically results in the staining of a segment of bowel 10 to 40 cm in length, which allowed for the operating surgeon to more accurately define the affected segment, resulting in more specific and successful surgery.<sup>16-18</sup> A similar technique has also been used to identify the source of OGIB in infants.<sup>19</sup>

More recently, Stauffer et al,<sup>20</sup> García-Barrasa et al,<sup>21</sup> and Stanojević et al<sup>22</sup> have also successfully used this tech-

nique. Localizing OGIB intraoperatively by fluorescein injection through a superselectively placed catheter has also been reported.<sup>23</sup> However, orange fluorescein dye is more tedious to use and requires the use of a UV Wood's lamp intraoperatively. The successful use of provocative angiography (ie, the administration of 5000 U of heparin systemically and 10 mg of tissue plasminogen activator injected during angiography directly into the superior mesenteric artery) followed by superselective injection of methylene blue has also been reported.<sup>24</sup> Of note, one of the limitations of our technique is that the hemorrhage has to be substantial and active at the time of the study in order to localize the source. Furthermore, when angiography can accurately locate an abnormality, the subsequent intraoperative localization of the bleeding point can still be a challenge. Superselective angiographic catheters have enabled interventional radiologists to cannulate distal visceral vessels and more accurately pinpoint the site of a lesion or bleeding. Intraoperative methylene blue injection causes a local, immediate, and dramatic demarcation of the small bowel that allows the suspected area to be well defined.<sup>25</sup> The recommended maximum intravascular dose is 1 to 2 mg/kg,<sup>17</sup> and each injection uses 0.5 mL of methylene blue (5 mg); thus, multiple injections can be made without reaching the maximum dose. Our small series of 4 cases exemplifies the problems that are commonly encountered in identifying the source of OGIB. Even though our cases all had pathology in the small bowel, we believe that this method could also be applied to cases with obscure colonic bleeding. Because surgery still offers the best chance for cure, we believe that SSMA combined with intraoperative localization with methylene blue dye plays an important role in the diagnostic and therapeutic workup of these challenging cases as an adjunct to standard endoscopic and radiological investigations. Larger prospective studies assessing the use of SSMA are warranted.

### ARTICLE INFORMATION

**Accepted for Publication:** January 31, 2013.

**Published Online:** May 29, 2013.  
doi:10.1001/jamasurg.2013.345.

**Author Affiliations:** Hepatopancreaticobiliary Surgical Unit, Department of Surgery and Cancer, Imperial College, Healthcare NHS Trust, Hammersmith Hospital, London, England (Pai, Frampton, Virk, Nehru, Kyriakides, Limongelli, Jiao); Department of Radiology, Imperial College, Healthcare NHS Trust, Hammersmith Hospital, London, England (Jackson).

**Author Contributions:** Dr Jiao had full access to all the data in the study and takes responsibility for the integrity of the data and the accuracy of the data analysis.

**Study concept and design:** Frampton, Limongelli, Jiao.

**Acquisition of data:** Pai, Virk, Nehru, Jackson.

**Analysis and interpretation of data:** Virk, Kyriakides, Jackson.

**Drafting of the manuscript:** Pai, Frampton, Virk, Nehru, Kyriakides.

**Critical revision of the manuscript for important**

**intellectual content:** Pai, Frampton, Limongelli, Jackson, Jiao.

**Statistical analysis:** Pai.

**Administrative, technical, and material support:** Kyriakides, Jackson.

**Study supervision:** Jiao.

**Conflict of Interest Disclosures:** None reported.

### REFERENCES

1. Szold A, Katz LB, Lewis BS. Surgical approach to occult gastrointestinal bleeding. *Am J Surg.* 1992;163(1):90-92; discussion 92-93.
2. Kochhar GS, Sanaka MR, Vargo JJ. Therapeutic management options for patients with obscure gastrointestinal bleeding. *Therap Adv Gastroenterol.* 2012;5(1):71-81.
3. Pennazio M, Arrigoni A, Risio M, Spandre M, Rossini FP. Clinical evaluation of push-type enteroscopy. *Endoscopy.* 1995;27(2):164-170.
4. Chong J, Tagle M, Barkin JS, Reiner DK. Small bowel push-type fiberoptic enteroscopy for patients with occult gastrointestinal bleeding or suspected small bowel pathology. *Am J Gastroenterol.* 1994;89(12):2143-2146.

5. Davies GR, Benson MJ, Gertner DJ, Van Someren RM, Rampton DS, Swain CP. Diagnostic and therapeutic push type enteroscopy in clinical use. *Gut.* 1995;37(3):346-352.

6. Di Girolamo G, Malavasi A, Cassisa L, Cossu ML, Dettori G, Realdi G. Chronic bleeding caused by small bowel angiodysplasia: a problem of recognition and diagnosis. *Ital J Gastroenterol.* 1992;24(8):468-469.

7. Eshpuniyani PB, Kantharia CV, Prabhu RY, Supe AN. Intraoperative localization of vascular malformation of small bowel by selective intra-arterial dye injection. *Saudi J Gastroenterol.* 2010;16(4):302-304.

8. Lau WY, Chu KW, Yuen WK, Poon GP, Li AK. Bleeding angiodysplasia of the gastrointestinal tract. *Aust N Z J Surg.* 1992;62(5):344-349.

9. Lewis BS, Wayne JD. Chronic gastrointestinal bleeding of obscure origin: role of small bowel enteroscopy. *Gastroenterology.* 1988;94(5, pt 1):1117-1120.

10. Zuckerman GR, Prakash C. Acute lower intestinal bleeding: part II, etiology, therapy, and outcomes. *Gastrointest Endosc*. 1999;49(2):228-238.
11. Parkes BM, Obeid FN, Sorensen VJ, Horst HM, Fath JJ. The management of massive lower gastrointestinal bleeding. *Am Surg*. 1993;59(10):676-678.
12. Browder W, Cerise EJ, Litwin MS. Impact of emergency angiography in massive lower gastrointestinal bleeding. *Ann Surg*. 1986;204(5):530-536.
13. Richter JM, Christensen MR, Colditz GA, Nishioka NS. Angiodysplasia: natural history and efficacy of therapeutic interventions. *Dig Dis Sci*. 1989;34(10):1542-1546.
14. Fogler R, Golembe E. Methylene blue injection: an intraoperative guide in small bowel resection for arteriovenous malformation. *Arch Surg*. 1978;113(2):194-195.
15. Athanasoulis CA, Moncure AC, Greenfield AJ, Ryan JA, Dodson TF. Intraoperative localization of small bowel bleeding sites with combined use of angiographic methods and methylene blue injection. *Surgery*. 1980;87(1):77-84.
16. Defreyne L, Verstraeten V, De Potter C, Pattyn P, De Vos M, Kunnen M. Jejunal arteriovenous malformation, diagnosed by angiography and treated by embolization and catheter-guided surgery: case report and review of literature. *Abdom Imaging*. 1998;23(2):127-131.
17. McDonald ML, Farnell MB, Stanson AW, Ress AM. Preoperative highly selective catheter localization of occult small-intestinal hemorrhage with methylene blue dye. *Arch Surg*. 1995;130(1):106-108.
18. Koga H, Iida M, Nagai E, et al. Jejunal angiodysplasia confirmed by intravascular injection technique in vitro: report of a case and review of the literature. *J Clin Gastroenterol*. 1996;23(2):139-144.
19. Mazziotti MV, Muldowney S, Darcy M, Hackett BP, Skinner MA. Intraoperative localization of small intestinal bleeding in an infant by methylene blue injection: a case report. *J Pediatr Surg*. 1998;33(5):754-755.
20. Stauffer JA, Shaddix KK, Achem SR, et al. Intra-operative use of super-selective or highly selective angiography with methylene blue injection to localize arterial-venous malformation. *Colorectal Dis*. 2011;13(4):e65-e66.
21. García-Barrasa A, Madrazo González Z, Domínguez Elías J, Soriano Izquierdo A. [Selective intraoperative methylene blue administration for severe lower gastrointestinal bleeding secondary to complicated jejunal diverticulum [in Spanish]. *Rev Esp Enferm Dig*. 2008;100(9):598-600.
22. Stanojević G, Bosnjaković P, Stojanović M, et al. Preoperative identification of bleeding site caused by angiodysplasia of the small bowel by means of selective arteriography and application of methylene blue [in Serbian]. *Vojnosanit Pregl*. 2010;67(12):1029-1032.
23. Ohri SK, Jackson J, Desa LA, Spencer J. The intraoperative localization of the obscure bleeding site using fluorescein. *J Clin Gastroenterol*. 1992;14(4):331-334.
24. Remzi FH, Dietz DW, Unal E, Levitin A, Sands MJ, Fazio VW. Combined use of preoperative provocative angiography and highly selective methylene blue injection to localize an occult small-bowel bleeding site in a patient with Crohn's disease: report of a case. *Dis Colon Rectum*. 2003;46(2):260-263.
25. Gifford SM, Peck MA, Reyes AM, Lundy JB. Methylene blue enteric mapping for intraoperative localization in obscure small bowel hemorrhage: report of a new technique and literature review: combined intraoperative methylene blue mapping and enterectomy. *J Gastrointest Surg*. 2012;16(11):2177-2181.