

Answer

Ruptured Ectopic Pregnancy

On arrival at our center, the patient's condition was hemodynamically stable (hemoglobin level, 8.8 g/dL). After we reviewed the CT scan, she was taken to the operating room for formal exploration. A large clot was found surrounding the suprahepatic vena cava. On evacuation of the hematoma, a pulsatile hemorrhage from the inferior phrenic artery was encountered and ligated. A spherical mass of fibrinous tissue was found adherent to the hepatic capsule and diaphragm (**Figure 2**). This was evacuated and sent for pathological analysis, along with the clot material. The hepatic capsule was intact, and intraoperative hepatic ultrasonography demonstrated a normal liver. No abnormality was noted in the pelvis. Pathological evaluation of the specimen demonstrated products of conception (**Figure 3**), confirming the diagnosis of intra-abdominal ectopic pregnancy with inferior phrenic artery parasitization and rupture. The patient's postoperative human chorionic gonadotropin level was 80 mIU/mL.

Ectopic pregnancies account for 1% of all conceptions; 98.3% of those are in the fallopian tubes.¹⁻³ Al-

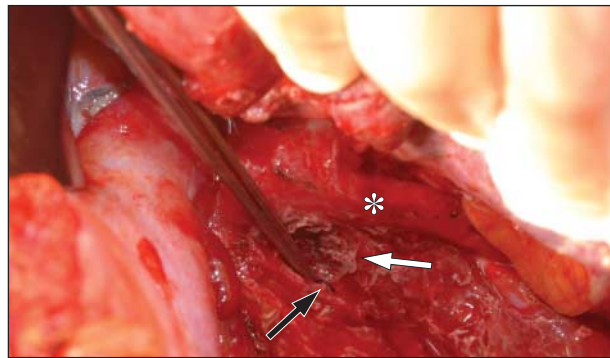


Figure 2. Pulsatile bleeding from the inferior phrenic artery was controlled intraoperatively with suture ligation (black arrow). A fibrinous mass of tissue was pulled from a small cavity in the diaphragm (white arrow) posterolateral to the inferior vena cava (asterisk).

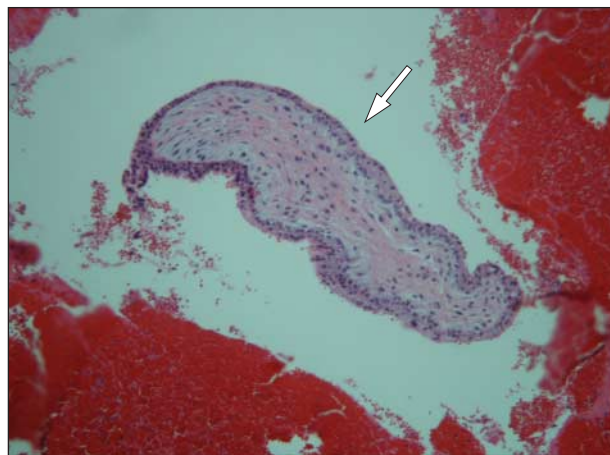


Figure 3. Pathological evaluation of the fibrinous tissue specimen demonstrated products of conception, including chorionic villi with surrounding trophoblastic cells (arrow; hematoxylin-eosin, original magnification $\times 100$).

though extremely rare (1.7% of all ectopic pregnancies), extrafallopian intra-abdominal pregnancies can cause devastating complications. A literature review found 14 reported cases of hepatic implantation in 35 years.^{1,4} The rich vascular supply of the liver makes it a favorable site for implantation, with the majority of reported cases having implantation on the inferior aspect of the right lobe.⁵ Most of these pregnancies are aborted spontaneously in the first trimester as a result of disruption of the implantation site from maternal hemorrhage due to trophoblastic invasion of the Glisson capsule. The resulting hemorrhage is often severe with subsequent maternal hypotension; hemorrhage is rare after the 12th week of gestation. One case reported expectant management of an uncomplicated hepatic pregnancy that resulted in delivery of a viable 1800-g newborn at 34 weeks' gestation.⁵

Intra-abdominal pregnancy should be suspected in women of child-bearing age with an elevated human chorionic gonadotropin level and no sign of intrauterine pregnancy on ultrasonography. The first step in diagnosis usually is pelvic ultrasonography to assess the fallopian tubes. If a tubal pregnancy is not seen, complete abdominal ultrasonography should be performed to inspect the peritoneal surfaces as well as the liver for possible implantation sites. Abdominal magnetic resonance imaging is also a useful tool for diagnosis if the results of ultrasonography are inconclusive. The unstable patient is often taken to surgery for diagnostic laparoscopy after intrauterine pregnancy is ruled out. The entire abdominal cavity must be explored, including inspection of the liver, if a tubal pregnancy is not identified.

Accepted for Publication: September 26, 2011.

Correspondence: W. Charles Conway, MD, Department of Surgery, Ochsner Medical Center, 1514 Jefferson Hwy, New Orleans, LA 70121 (wconway@ochsner.org).

Author Contributions: Study concept and design: Lyons and Conway. Acquisition of data: Lyons and Conway. Analysis and interpretation of data: Lyons and Halat. Drafting of the manuscript: Lyons, Halat, and Conway. Critical revision of the manuscript for important intellectual content: Lyons and Conway. Study supervision: Conway.

Financial Disclosure: None reported.

REFERENCES

1. Delabrousse E, Site O, Le Mouel A, Riethmuller D, Kastler B. Intrahepatic pregnancy: sonography and CT findings. *AJR Am J Roentgenol.* 1999;173(5):1377-1378.
2. Anderson PM, Opfer EK, Busch JM, Magann EF. An early abdominal wall ectopic pregnancy successfully treated with ultrasound guided intralesional methotrexate: a case report. *Obstet Gynecol Int.* 2009;2009:247452. doi:10.1155/2009/247452.
3. Gibbs A, ed. *Danforth's Obstetrics and Gynecology.* 10th ed. Philadelphia, PA: Lippincott Williams & Wilkins; 2008.
4. Shippey SH, Bhoola SM, Royek AB, Long ME. Diagnosis and management of hepatic ectopic pregnancy. *Obstet Gynecol.* 2007;109(2, pt2):544-546.
5. Ramphal SR, Moodley J, Rajarathnam D. Hepatic pregnancy managed conservatively. *Trop Doct.* 2010;40(2):121-122.