

Image of the Month

Peter J. Kneuert, MD; Midhun Malla, MBBS; David P. Cosgrove, MD; Joseph M. Herman, MD, MSc; Ihab R. Kamel, MD, PhD; Jean-Francois H. Geschwind, MD; Andrew M. Cameron, MD; Timothy M. Pawlik, MD, MPH, PhD

A 71-YEAR-OLD ASIAN MAN WITH A HISTORY of cadaveric orthotopic liver transplant for hepatocellular carcinoma (HCC) in the background of hepatitis B cirrhosis 10 years earlier presented with a 6-month history of decreased appetite, decreased energy level, and slowly increasing α_1 -fetoprotein level. The patient also reported a frequent urge to urinate, nocturia, and difficulty voiding his bladder. These symptoms were attributed to benign prostatic enlargement, and the patient underwent transurethral resection of the prostate by his local urologist. The patient developed abdominal pain, fever, and signs of septic shock postoperatively. A computed tomographic scan showed a large necrotic pelvic mass involving the prostate that extended to the sigmoid colon. Because a localized abscess was suspected, an image-guided drain was placed that returned necrotic tissue but no obvious purulence. After he recovered from the septic shock and his condition was stabilized in the intensive care unit, the patient was transferred to our institution for further treatment.

At presentation, the patient had an indwelling Foley catheter that was draining brown, cloudy urine. Laboratory test results indicated mild anemia (hemoglobin level, 10.1 g/dL) and normal transaminase levels (aspartate aminotransferase/alanine aminotransferase, 27/23 U/L) but an elevated bilirubin level of 9.2 mg/dL and an α_1 -fetoprotein level of 280 ng/mL. (To convert hemoglobin to grams per liter, multiply by 10; aspartate aminotransferase and alanine aminotransferase to microkatal per liter, multiply by 0.0167; bilirubin to micromoles per liter, multiply by 17.104; and α_1 -fetoprotein to micrograms per liter, multiply by 1.) We obtained another computed tomographic image, which demonstrated a large necrotic pelvic mass measuring 8.7×7.3 cm and extending to the sigmoid colon with associated wall thickening (**Figure 1**). The mass communicated with the prostate and the urinary bladder (**Figure 2**). Although there were no focal lesions in the liver allograft, we noted radiographic evidence of portal hypertension, including prominent venous collaterals in the left side of the upper abdomen.

Author Affiliations: Departments of Surgery (Drs Kneuert, Cameron, and Pawlik), Medical Oncology (Drs Malla and Cosgrove), Radiation Oncology (Dr Herman), Radiology (Dr Kamel), and Interventional Radiology (Dr Geschwind), The Sidney Kimmel Comprehensive Cancer Center, The Johns Hopkins University School of Medicine, Baltimore, Maryland.

What Is the Diagnosis?

- A. Perforated rectosigmoid cancer
- B. Diverticular abscess
- C. Recurrent metastatic HCC
- D. Advanced prostate cancer

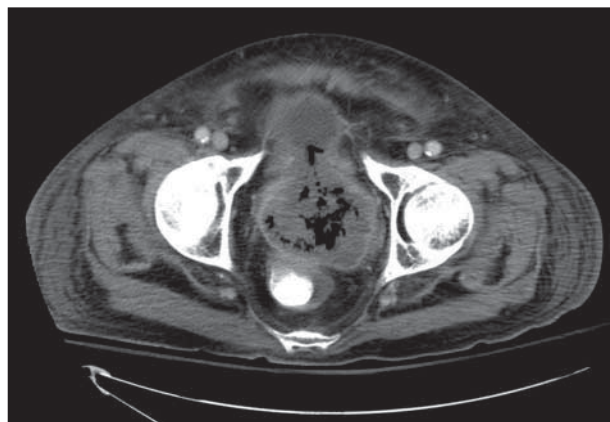


Figure 1. Axial computed tomographic image demonstrating a large necrotic pelvic mass involving the prostate and urinary bladder, with air resulting from an indwelling Foley catheter.

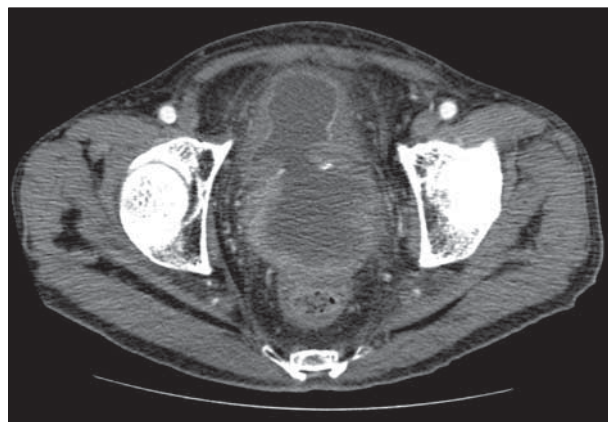


Figure 2. Axial computed tomographic image of the pelvic mass demonstrating direct extension to the rectum and a fistula to the urinary bladder.