Image of the Month

Antonio Pio Tortorelli, MD; Sergio Alfieri, MD; Alejandro Martin Sanchez, MD; Fausto Rosa, MD; Giovanni Battista Doglietto, MD

An 18-year-old man had a 3-month history of worsening diffuse abdominal pain irradiating to the back, abdominal distension, malaise, weight loss (10 kg), and diarrhea. Six months before that, he presented with bilateral exophthalmos of uncertain origin (ie, an absence of endocrine or intracranial pathologies); in particular, his thyroid function test results were within the normal range (thyrotropin level, 1230 mIU/L; free triiodothyronine level, 380 pg/dL [to convert to picomoles per liter, multiply by 0.0154]; free thyroxine level, 12.9 ng/dL [to convert to picomoles per liter, multiply by 12.871]). A computed tomographic scan of the abdomen (**Figure 1**) revealed a bulky heterogeneous solid mass (33×27×18 cm) with large necrotic and cystic areas that was located in the abdominal cavity up to the pelvis and that was in close contact with the left hepatic lobe, the posterior surface of the stomach (adjacent to the minor curvature), the pancreatic head, the transverse colon, the mesenteric root, and the retroperitoneal vessels, without clear cleavage planes. The body and the tail of the pancreas were not identifiable. No ascitic fluid, enlarged lymph node, peritoneal nodule, or liver metastasis was detected. After injection of the contrast medium, the mass was revealed to have intense arterial vascularization. Routine laboratory studies revealed that additional liver function test results were within the normal range (albumin level, 4.1 g/dL [to convert to grams per liter, multiply by 10]; hemoglobin level, 9.1 g/dL [to convert to grams per liter, multiply by 10]). His white blood cell count was normal, and his serum tumor markers were within the normal range, except for his cancer antigen 125 level, which was elevated at 145.5 U/mL [to convert to kilounits per liter, multiply by 1.0]. His neuron-specific enolase, gastrin, and chromogranin A serum levels were normal (6.5 ng/mL, 72 pg/mL [to convert to picomoles per liter, multiply by 0.481], and 34.632 pmol/mL, respectively). After surgical excision, the severity of exophthalmos was significantly reduced.

Author Affiliations: Digestive Surgery Division, Department of Surgical Sciences, Catholic University, School of Medicine, Rome, Italy.

What Is the Diagnosis?

A. Gastrointestinal stromal tumor of the stomach
B. Primitive neuroectodermal tumor (PNET) of the pancreas
C. Pancreatic solid pseudopapillary tumor
D. Retroperitoneal hemangiosarcoma

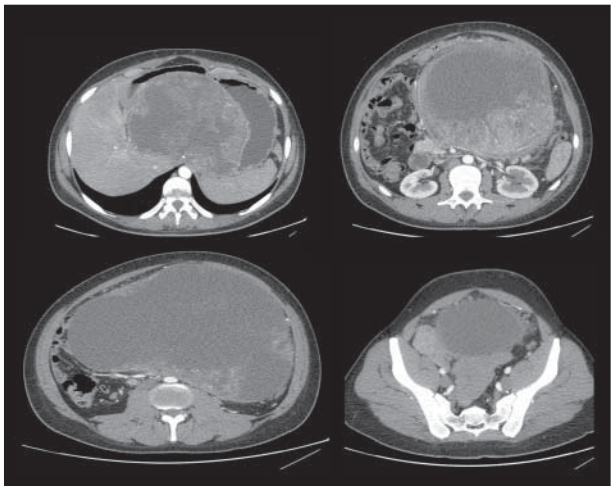

Figure 1. Computed tomographic scans showing a huge solid and cystic mass extending from the hepatoduodenal ligament to the pelvis, with adhesion/infiltration of the minor curvature of the stomach, left liver lobe, pancreas, and retroperitoneal vessels.

©2012 American Medical Association. All rights reserved.
Downloaded From: http://archsurg.jamanetwork.com/ on 01/24/2017