

## Image of the Month

Mariana Chavez, MD; Jennifer Dannel, MD; Ronald Miick, MD; Doraid Jarrar, MD; Kamran Khanmoradi, MD; Jorge Ortiz, MD

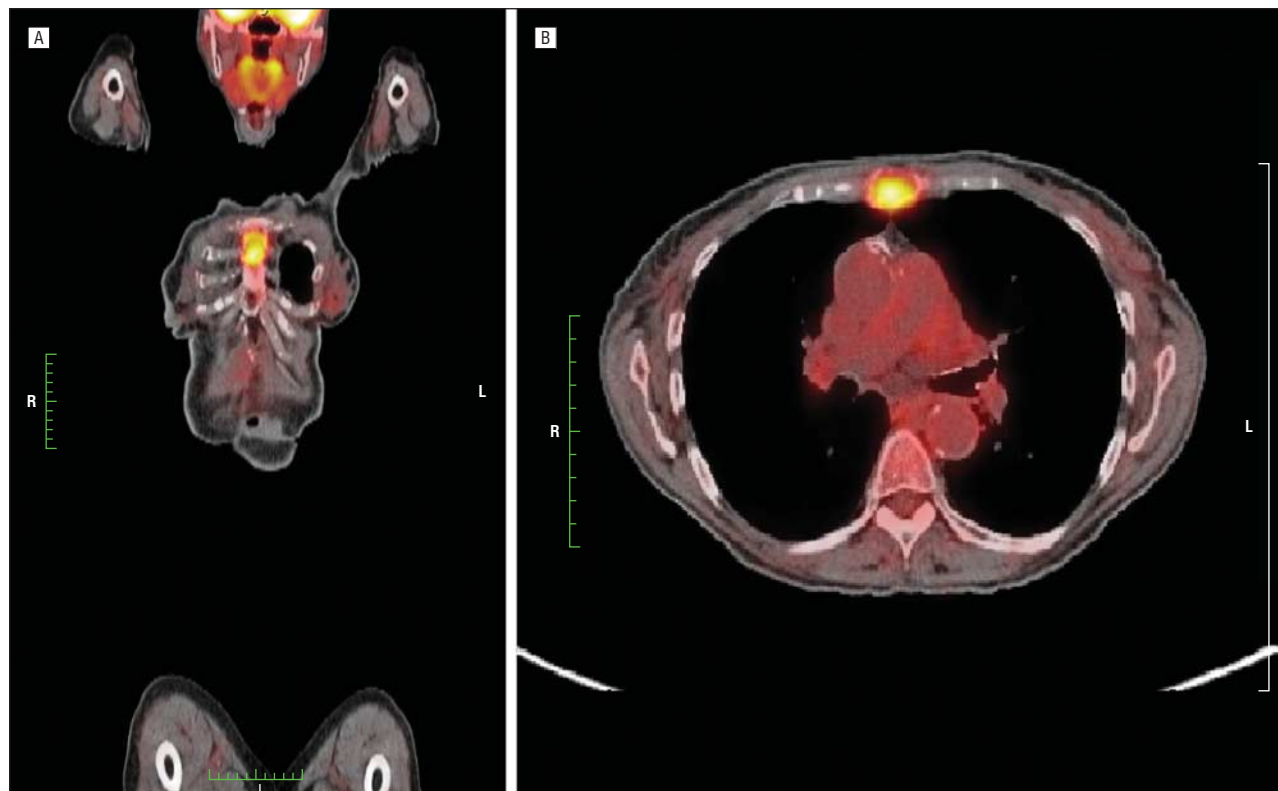
**A** 68-YEAR-OLD WOMAN WITH HEPATOCELLULAR carcinoma (HCC) underwent a liver transplant (LT). On preoperative evaluation, she had an  $\alpha_1$ -fetoprotein level of 43.7 ng/mL (normal range, <8 ng/mL [to convert to micrograms per liter, multiply by 1.0]), and a computed tomographic (CT) scan of her chest and a bone scan both had negative results. Her tumor was within the Milan criteria. Her native liver explant revealed a T2 lesion without vascular invasion or lymph nodes positive for tumor. One month later, she underwent a retransplant owing to hepatic artery disruption. The liver pathology only showed ischemia. The patient had a satisfactory recovery.

She presented to the emergency department a year later complaining of nausea, vomiting, and weight loss (6.3 kg [14 lb]). On physical examination, she was anicteric,

afebrile, and normotensive with no hepatomegaly. Her workup included a white blood cell count of 3800 cells/ $\mu$ L (normal range, 4-11 cells/ $\mu$ L [to convert to  $\times 10^9/L$ , multiply by 0.001]), a hemoglobin level of 7.6 g/dL (normal range, 12-16 g/dL [to convert to grams per liter, multiply by 10.0]), a creatinine level of 1.3 mg/dL (normal range, 0.7-1.5 mg/dL [to convert to micromoles per liter, multiply by 88.4]), normal albumin and liver enzyme levels, and a normal coagulation profile. Imaging studies included magnetic resonance imaging of the abdomen, CT angiography, a chest CT scan, a bone scan, and ultrasonography, all of which had negative results. She subsequently underwent a positron emission tomographic/CT scan (**Figure 1**).

### What Is the Diagnosis?

- A. Osteomyelitis
- B. Chondrosarcoma
- C. Multiple myeloma
- D. Bone metastases from HCC



**Figure 1.** A and B, Fludeoxyglucose F18-positron emission tomographic/computed tomographic scans showing increased uptake in the upper half of the sternal body. L indicates left; and R, right.