

Extracolonic Manifestations of Familial Adenomatous Polyposis After Proctocolectomy

Hagit Tulchinsky, MD; Andrei Keidar, MD; Hana Strul, MD; Gideon Goldman, MD; Joseph M. Klausner, MD; Micha Rabau, MD

Hypothesis: Extracolonic manifestations have a major effect on the morbidity and mortality of patients with familial adenomatous polyposis following proctocolectomy.

Design: Case review study.

Setting: Colorectal unit, university-affiliated hospital.

Patients: Fifty patients (25 males and 25 females) with familial adenomatous polyposis WHO underwent proctocolectomy between January 1988 and October 2003.

Interventions: Ileal pouch–anal anastomosis (n=41), Kock pouch (n=1), end ileostomy (n=6). Two patients underwent total colectomy with an ileorectal anastomosis.

Main Outcome Measures: Clinical follow-up and telephone interview; contact with clinicians following up patients elsewhere.

Results: The patients' median age at surgery was 33 years. The mean length of follow-up was 74 months. Four patients were lost to follow-up. Extracolonic manifestations were diagnosed in 38 patients (76%). Twelve pa-

tients had 14 desmoid tumors: 7 were treated surgically and 7 medically (these patients received celecoxib and tamoxifen citrate therapy). Of the 41 patients who underwent upper gastrointestinal tract endoscopy, 11 developed duodenal and/or ampullary adenomas. Three patients had endoscopic polypectomy and 1 underwent a Whipple operation. Among the 29 patients who underwent pouchoscopy, 5 had pouch adenomas and 3 had adenomas that were found in the rectal stump. Two patients died—one of a huge mesenteric desmoid tumor and the other of an aggressive mesenteric malignant fibrous histiocytoma.

Conclusions: Long-term morbidity and mortality were strongly related to the development of mesenteric tumors and ampullary-duodenal polyps. Early detection of desmoid tumors, duodenal, pouch, and rectal cuff adenomas by periodic computed tomography, gastroduodenoscopy, and pouchoscopy, respectively, may allow control by medical therapy, endoscopy, or limited surgical procedures. In most patients control of desmoid tumors was achieved using a combination of celecoxib and tamoxifen citrate therapy.

Arch Surg. 2005;140:159-163

FAMILIAL ADENOMATOUS POLYPOSIS (FAP) is an inherited autosomal dominant disorder that affects 1 to 8 per 10 000 persons, both sexes equally, and has been reported in all racial and ethnic groups.^{1,2} Usually beginning in the subject at puberty, FAP is characterized by the development of hundreds to thousands of adenomatous polyps in the colon and rectum with a tendency

changed the pattern of morbidity and mortality. Today, the development of desmoid tumors and of duodenal and ileal pouch adenomas are the focus of special attention and lifelong surveillance. We describe our 15-year experience with patients who had FAP after proctocolectomy to determine the extent to which extracolonic manifestations affect morbidity and mortality.

Author Affiliations: Colorectal Unit, Department of Surgery B (Drs Tulchinsky, Keidar, Goldman, Klausner, and Rabau) and Gastroenterology (Dr Strul), Tel Aviv Sourasky Medical Center, affiliated with the Sackler School of Medicine, Tel Aviv University, Tel Aviv, Israel. Dr Keidar is now with the Department of Surgery B, Meir Hospital, Kfar Saba, Israel.

See Invited Critique at end of article

to undergo malignant transformation.³ Colorectal cancer was once the main cause of mortality⁴: the establishment of national registries, early diagnosis, and prophylactic proctocolectomy have reduced the risk of colorectal adenocarcinoma and

METHODS

PATIENTS

All patients with FAP operated on in our department between January 1988 and October 2003 were eligible for inclusion in this study. These patients' conditions were followed up routinely in the surgical and gastroenterological outpatient clinics. Review of the case notes was supplemented by telephone interview or

Table 1. Precolectomy Extracolonic Manifestations

Manifestation	No. of Patients
Upper gastrointestinal tract polyps	11
Stomach	7
Duodenum	6
Papilla	2
Osteomas	6
Desmoid tumor	0
Fibrous bone dysplasia	1
Thyroid nodule	1
Papillary cancer of thyroid	1
Pinealoblastoma	1
Skin fibromata	1
Benign brain cyst	1
Retinal hyperpigmentation	1

Table 2. Familial Adenomatous Polyposis–Associated Gastrointestinal Tract and Extracolonic Manifestations

Manifestation	No. of Patients (n = 38)	No. of Patients Who Underwent Surgery
Upper gastrointestinal tract polyps	20	20
Stomach	13	0
Duodenum	14	4
Periampullary	1	1
Papilla	4	3*
Osteomas	15	1
Desmoid tumor	12	7
Malignant fibrous histiocytoma	1	1
Fibrous bone dysplasia	1	
Thyroid nodule	1	
Papillary cancer of thyroid	1	1
Pinealoblastoma	1	1
Skin fibromata	3	
Benign brain cyst	1	
Retinal hyperpigmentation	1	
Pouch adenoma	5	
Adenoma in anorectal mucosa	3	3†

*Endoscopic polypectomy and/or papillectomy.

†Endoscopic resection in 2 patients and surgical polypectomy in 1 patient.

contact with clinicians following up some of these patients elsewhere. The retrieved data included demographics and background diseases, indications for and types of operative interventions, extracolonic manifestations, and further interventions relevant to the disease.

STATISTICAL ANALYSIS

Statistical analysis was performed using the SAS System for Windows, version 8.01 (SAS Institute Inc, Cary, NC).

RESULTS

Fifty patients (25 males and 25 females) with FAP underwent surgery. Their median age at the time of colectomy was 33 years (age range, 13-61 years). The diagnosis was based on endoscopic findings, and an active protein C gene mutation was identified in 31 patients. Twenty-seven patients were derived from 11 families. Forty-eight patients eventually underwent proctocolectomy: 41 (84%) had res-

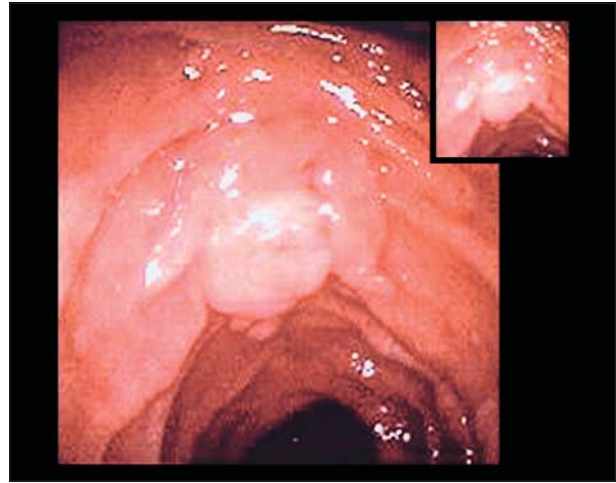


Figure 1. Side-view duodenoscopy of a duodenal adenoma.

toration of continuity with an ileal pouch–anal anastomosis (IPAA), 1 had a Kock pouch, and 6 had an end ileostomy. Six patients underwent total abdominal colectomy with an ileorectal anastomosis (IRA) as the initial procedure: 1 failed conversion to IPAA, 2 were converted to IPAA, and 1 was converted to a Kock pouch. Two patients still have an IRA. Among the patients with IPAA, 22 had a stapled anastomosis and 19 had a mucosectomy with hand-sewn anastomosis. The mean follow-up duration was 74 months (range, 3-288 months). Four patients were lost to follow-up. We report these data about 46 patients.

Eight 8 patients (16%) had colorectal carcinoma. It was diagnosed before surgery in 3 patients, intraoperatively in 4 patients, and developed in the rectal stump during the follow-up period in 1 patient.

The baseline precolectomy extracolonic manifestations of the study patients are given in **Table 1**. Upper gastrointestinal tract endoscopy was done on 39 patients before surgery. There were no untoward findings in 27 patients after undergoing physical examination. Eleven patients had fundic gland polyps or duodenal adenomas with low-grade dysplasia or both. Precolectomy abdominal imaging (computed tomographic scan or ultrasonography) was done in 36 patients and found to have no abnormal findings for any abdominal tumor.

The extracolonic manifestations found at operation and during follow-up are summarized in **Table 2**. Eight patients were diagnosed as having phenotypic Gardner syndrome (FAP accompanied by osteomas, epidermoid cysts, dental abnormalities, and desmoid tumors) expression and 1 with a variant of Turcot syndrome type 2 (FAP and medulloblastoma). The most common manifestations were osteomas, occurring in 15 patients of whom only 2 were symptomatic. One patient underwent an osteotomy for dental malocclusion, and 1 has hypoacusis due to an osteoma in the external auditory meatus. Forty-one patients (7%) underwent upper gastrointestinal tract endoscopy using a side-viewing duodenoscope. Twenty patients (49%) had polyps of which 65% of these polyps were of the benign fundic gastric type. Fourteen patients (70%) had duodenal polyps of which 1 polyp was periampullary and 4 polyps were located in the papilla (**Figure 1**). Thirteen patients (65%) had adenomas with low-grade dysplasia: 3 underwent en-

Table 3. Desmoid Tumors

Patient No.	Presence of Gardner Syndrome	Time of Diagnosis	Interval Since First Operation, mo	Location	Surgical Procedure	Indication	Medical Treatment Received	Status at Last Follow-up Visit	Outcome
1	Yes	At follow-up	16	Retroperitoneum	R nephrostomy	Ureteral, obstruction	Tamoxifen citrate and celecoxib*	Regression, nephrostomy	Alive
2	Yes	At follow-up	34	Mesentery	SB resection, bypass, unresectable	SBO	Tamoxifen and celecoxib	No change	Alive
3	Yes	At follow-up	8	Mesentery	No		Tamoxifen and sulindac	Progression, dead	Dead
4	Yes	At follow-up	9	Mesentery	No		Tamoxifen and celecoxib	Complete regression	Alive
		At follow-up	15	Abdominal wall	Resection, mesh repair	Cosmetic		No desmoid tumor	
5	No	At follow-up	14	Mesentery	No		Tamoxifen and celecoxib	No change	Alive
6	Yes	At follow-up	40	Mesentery	No		Tamoxifen and celecoxib	Regression	Alive
7	Yes	At follow-up	26	Mesentery	Partial resection and SB resection	SBO	Tamoxifen and celecoxib	Regression	Alive
8	No	At follow-up	50	Abdominal wall	Resection	Cosmetic	Tamoxifen and celecoxib	No desmoid tumor	Alive
		At follow-up	234	Retrorectal	No			No change	
9	No	Operation 1	0	Mesentery	Resection and SB resection	Small incidental	Tamoxifen and celecoxib	No desmoid tumor	Alive
10	Yes	Operation 2	162	Mesentery	Resection and SB resection	Bleeding	Tamoxifen and celecoxib	No desmoid tumor	Alive
11	No	Operation 2	167	Mesentery	No		Tamoxifen and celecoxib	No change	Alive
12	No†	At follow-up	16	Mesentery	No		Tamoxifen and celecoxib	No change	Alive

Abbreviations: SB, small-bowel; SBO, small-bowel obstruction.

*The following doses were given: tamoxifen citrate, 120 mg/d, and celecoxib, 800 mg/d.

†This patient had Turcot syndrome type 2.

doscopy polypectomy of which 2 required completion endoscopic papillectomy and both had recurrent adenomas with low-grade dysplasia at last follow-up. One patient who had a periampullary adenoma with high-grade dysplasia underwent an uneventful Whipple operation.

Thirty-seven patients (90%) with an IPAA were followed up: 29 had periodic endoscopy and biopsy specimens obtained from the ileal pouch and 5 had tubular adenomas with low-grade dysplasia that were resected endoscopically. One patient had severe ulcerations of the pouch and was found to have Crohn disease. Three of 17 patients with a stapled IPAA were found to have adenomas with low-grade dysplasia in the residual anorectal mucosa. Two polyps were resected endoscopically and 1 surgically. No invasive cancer was found.

Fourteen desmoid tumors were identified in 12 patients (26%), during or after surgery. None of these patients had a desmoid tumor before surgery. The tumor location, time of diagnosis, and interval from the first operation, indication for the operation, surgical procedure, medical treatment, and patient's status at last follow-up visit are listed in **Table 3**. Most desmoid tumors were diagnosed during the follow-up period; the median interval from the first laparotomy was 26 months (range, 8-234 months). One patient was operated on 15

years after having an IRA because of numerous rectal polyps. During surgery, a mesenteric desmoid was found that precluded the performance of an IPAA procedure, and the patient underwent proctectomy and ileostomy. One patient was diagnosed as having pinealoblastoma, papillary thyroid carcinoma, and multiple colonic polyps and was considered as probably having a variant of Turcot syndrome type 2. Multiple mesenteric desmoid tumors developed in this patient 16 months after IPAA. The surviving 11 patients are being treated with a combination of tamoxifen citrate, 120 mg/d, and the cyclooxygenase 2 inhibitor celecoxib, 800 mg/d, and the disease is stable or in regression in all, including 2 patients who were operated on for small-bowel obstruction, 10 and 6 years ago, and 1 patient with hydronephrosis that was relieved by nephrostomy (**Figure 2**). In 1 patient, the tumor decreased in size during 4 years of follow-up. There has been no tumor recurrence in the patients who were treated in an adjuvant setup after excision.

Two patients died. One patient who had been lost to follow-up was admitted to the hospital 5½ years after colectomy and ileorectal anastomosis because of an acute abdomen and underwent emergent surgery. This patient had small-bowel perforation due to an aggressive mesenteric tumor that was found on histologic study to

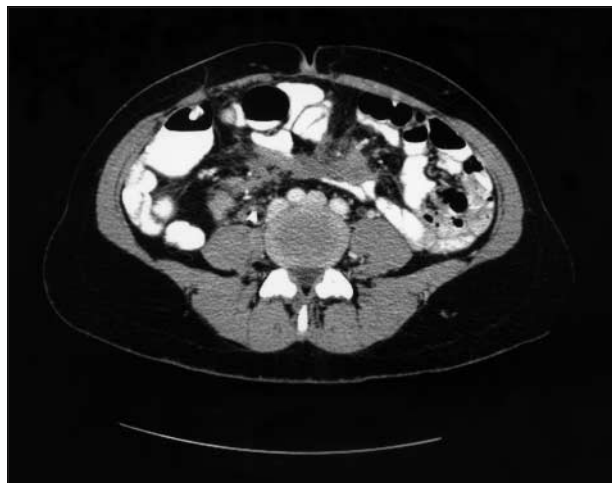


Figure 2. Computed tomographic view of a desmoid tumor infiltrating the mesenteric root.

be a malignant fibrous histiocytoma. The patient died a few months later owing to intra-abdominal tumor spread. The other patient had a huge intra-abdominal desmoid tumor and died 9 months after IPAA. The tumor was already identified at operation: it was 1 cm in diameter, situated in the small-bowel mesentery, grew perniciously to huge extensions (>30 cm), and caused deep vein thrombosis and a fatal pulmonary embolism.

COMMENT

For many years, the main cause of mortality in patients with FAP was colorectal cancer.^{4,5} In 1925, Lockhart-Mummery³ demonstrated that prophylactic examination of family members at risk and colectomy in affected individuals reduced the frequency of colorectal cancer, leading to the founding of the St Mark's Hospital Polyposis Registry as the first polyposis registry in the world. In 1985, the Leeds Castle Polyposis Group was established as an international polyposis research forum.⁶ Polyposis registries have since been established in many countries, and this brought about a decrease in colorectal cancer prevalence and overall improvement in prognosis.^{7,8} It is well recognized that patients afflicted with the syndrome must undergo prophylactic surgery to extirpate the large bowel, which carries a 100% risk of developing cancer.⁹

There is some debate in the literature on IRA vs IPAA in a selected group of patients, with proponents of the IRA citing the relatively low morbidity, better quality of life, and ease of surveillance as benefits of the technique.^{10,11} Studies that evaluated these 2 techniques in patients with FAP, however, have failed to show a greater morbidity and poorer functional outcome for IPAA compared with IRA.¹² Some studies showed that IRA is associated with substantial mortality due to rectal cancer, regardless of the length of follow-up.¹³

The mortality pattern of patients with polyposis has changed substantially, and the most frequent causes of death in patients whose conditions were detected through screening are desmoid tumors and duodenal cancer.¹⁴ In countries with regular surveillance, such as in the Scandinavian region, cases of colorectal cancer in patients with

polyposis have become rare and occur almost entirely in probands who represent a new mutation.⁸ We have had no mortality from colorectal cancer in our current series. There is 1 patient who had a recurrence 37 months after resection of stage III carcinoma.

Among the great variety of extracolonic manifestations of FAP, there are 3 manifestations that require special attention and lifelong surveillance. The first appears in the form of adenomatous polyps of the stomach, duodenum, and small bowel and occurs in almost 100% of patients with FAP. Gastric cystic fundic gland polyps are common but rarely associated with malignancy.¹⁵ The second portion of the duodenum, especially the periampullary area, is the one prone to adenomatous transformation. Three percent to 8% of patients eventually have duodenal or periampullary cancer, a risk that increases if there is a family history of such occurrence.¹⁴ A 10-year prospective study by Groves et al¹⁶ reported that 6 of 114 patients with FAP developed duodenal adenocarcinoma. In our series, 10 (20%) of 50 patients had duodenal polyps. One patient had pancreaticoduodenectomy due to adenoma with high-grade dysplasia. Adenomas of the gastric antrum and other portions of the small bowel also occur but with lesser frequency.

The second manifestation is the development of adenomas within the ileal pouch several years after restorative proctocolectomy. The reported incidence ranges between 20% and 62% and depends on duration of follow-up.¹⁷⁻¹⁹ Parc et al²⁰ found that the risk of developing adenomas at 5, 10, and 15 years was 7%, 35% and 75%, respectively. The incidence was about 5 (17%) in our group of 29 patients, a figure that correlates well with the aforementioned data. The risk of cancer development in such adenomas has not been established. Patients with FAP are also at risk of developing adenomas and cancer in the anal transitional zone.^{21,22} In our series, 9 (18%) patients in the stapled IPAA group developed adenomas in the retained rectal mucosa. No cancer was found.

The third and major cause of morbidity and mortality in patients with FAP is abdominal desmoid tumors, the incidence of which ranges between 7% and 17% during a lifetime.^{23,24} Our incidence of 26% is higher than the reported one. Desmoid tumors are histologically benign and do not metastasize, but they do tend to invade locally. Mesenteric desmoid tumors may cause small-bowel obstruction or ischemia, hydronephrosis, or the formation of fistulas. It has long been recognized that surgical trauma triggers the development of desmoid tumors.²⁵ In the reported cases in our series, all tumors but 2 (82%) of the tumors appeared after surgery. Heiskanen and Järvinen²⁴ analyzed 202 patients with FAP and found that 83% developed desmoid tumors postoperatively. Together these findings support the contention that the approach to these benign, but aggressive, tumors should be conservative. Surgery may be hazardous by involving major small-bowel resection, and the recurrence rate after debulking is high, ranging between 75% and 85%. Therefore, surgery is reserved for life-threatening complications.²⁶

Radiotherapy and chemotherapy are associated with high complication rates, and their efficacy is questionable.²⁶ Although controversial, chemoprevention has been shown in some studies to be effective in reducing the num-

ber of adenomatous polyps, mainly in the colon.²⁷⁻²⁹ The treatment with sulindac and tamoxifen has been documented to restrain the growth of desmoid tumors, and even cases of regression have been reported.³⁰ Control of desmoid tumors with the combined treatment of a cyclooxygenase 2 inhibitor and tamoxifen was achieved in most of our patients. The mortality rate in our small group of patients was 9% (1 of 12 patients), but it reached 22% in larger series with longer follow-up.²⁶

An important issue is the choice of a prophylactic colorectal procedure in light of possible desmoid tumor formation. After IRA and IPAA, the risk has been estimated to be 12% and 17%, respectively.²⁴ Most centers have preferred IPAA to IRA over the past decade. When a desmoid tumor is found at the time of the first laparotomy, IPAA should be seriously considered, if technically feasible. The reason for this is that up to 34% of patients may require further surgery after colectomy and IRA because of uncontrollable rectal polyps or cancer,²⁶ and conversion may not be feasible because of the presence of a mesenteric desmoid tumor, as had occurred in one of our patients. The genetic susceptibility, family history of desmoid tumors, and early age at diagnosis should be considered when the choice of operation is made.³¹

CONCLUSIONS

The 2 main causes of long-term morbidity and mortality are adenomas in the upper gastrointestinal tract, pouch, and anorectal mucosa and desmoid disease. Long-term surveillance by gastroduodenoscopy and pouchoscopy in all patients with FAP are mandatory and computed tomographic scanning in high-risk patients should be considered. Early detection may allow control of this life-threatening condition by means of medical therapy and an endoscopic or limited surgical procedure. Further research should be aimed at the prevention and treatment of these growths to improve survival. A prospective study on the role of chemopreventive treatment in patients prone to develop desmoid tumors is warranted.

Accepted for Publication: September 29, 2004.

Correspondence: Hagit Tulchinsky, MD, Colorectal Unit, Department of Surgery B, Tel-Aviv Sourasky Medical Center, 6 Weitzman St, Tel Aviv, Israel 64239 (hagitt@tasmc.health.gov.il).

Acknowledgment: We thank Esther Eshkol, MA, for editorial assistance and Yaara Dgani for assistance in data collecting.

REFERENCES

- Phillips RKS, Spigelman AD, Thomson JPS, eds. *Familial Adenomatous Polyposis and Other Polyposis Syndromes*. London, England: Edward Arnold Publisher; 1994.
- Hampel H, Peltomaki P. Hereditary colorectal cancer: risk assessment and management. *Clin Genet*. 2000;58:89-97.
- Lockhart-Mummery P. Cancer and heredity. *Lancet*. 1925;1:427-429.
- Arvanitis ML, Jagelman DG, Fazio VN, Lavery IC, McGannon E. Mortality in patients with familial adenomatous polyposis. *Dis Colon Rectum*. 1990;33:639-642.
- Belchetz LA, Berk T, Bapat BV, Cohen Z, Gallinger S. Changing causes of mortality in patients with familial adenomatous polyposis. *Dis Colon Rectum*. 1996;39:384-387.
- Northover JM. Activities of the Leeds Castle Polyposis Group. *Semin Surg Oncol*. 1987;3:118-119.
- Galle TS, Juel K, Bülow S. Causes of death in familial adenomatous polyposis. *Scand J Gastroenterol*. 1999;34:808-812.
- Bulow S. Results of national registration of familial adenomatous polyposis. *Gut*. 2003;52:742-746.
- Debinski HS, Love S, Spigelman AD, Phillips RK. Colorectal polyp counts and cancer risk in familial adenomatous polyposis. *Gastroenterology*. 1996;110:1028-1030.
- Bulow C, Vasen H, Jarvinen H, Bjork J, Bisgaard ML, Bulow S. Ileorectal anastomosis is appropriate for a subset of patients with familial adenomatous polyposis. *Gastroenterology*. 2000;119:1454-1460.
- Günther K, Braunrieder G, Bittorf BR, Hohenberger W, Matzel KE. Patients with familial adenomatous polyposis experience better bowel function and quality of life after ileorectal anastomosis than after ileoanal pouch. *Colorectal Dis*. 2003;5:38-44.
- Tonelli F, Valanzano R, Monaci I, Mazzoni P, Anastasi A, Ficari F. Restorative proctocolectomy or rectum-preserving surgery in patients with familial adenomatous polyposis: results of a prospective study. *World J Surg*. 1997;21:653-659.
- Vasen HF, van Duijvendijk P, Buskens E, et al. Decision analysis in the surgical treatment of patients with familial adenomatous polyposis: a Dutch-Scandinavian collaborative study including 659 patients. *Gut*. 2001;49:231-235.
- King JE, Dozois RR, Lindor NM, Ahlquist DA. Care of patients and their families with familial adenomatous polyposis. *Mayo Clin Proc*. 2000;75:57-67.
- Wallace MH, Phillips RK. Upper gastrointestinal disease in patients with familial adenomatous polyposis. *Br J Surg*. 1998;85:742-750.
- Groves GJ, Saunders BP, Spigelman AD, Phillips RK. Duodenal cancer in patients with familial adenomatous polyposis (FAP): results of a 10-year prospective study. *Gut*. 2002;50:636-641.
- Polese L, Keighley MR. Adenomas at resection margins do not influence the long-term development of pouch polyps after restorative proctocolectomy for familial adenomatous polyposis. *Am J Surg*. 2003;186:32-34.
- Parc Y, Piquard A, Dozois RR, Parc R, Tiret E. Long term outcome of familial adenomatous polyposis patients after restorative colectomy. *Ann Surg*. 2004;239:378-382.
- Thompson-Fawcett MW, Marcus VA, Redston M, Cohen Z, McLeod RS. Adenomatous polyps develop commonly in the ileal pouch of patients with familial adenomatous polyposis. *Dis Colon Rectum*. 2001;44:347-353.
- Parc YR, Olschwang S, Desaint B, Schmitt G, Parc RG, Tiret E. Familial adenomatous polyposis: prevalence of adenomas in the ileal pouch after restorative proctocolectomy. *Ann Surg*. 2001;233:360-364.
- Remzi FH, Church JM, Bast J, et al. Mucosectomy vs. stapled ileal pouch-anal anastomosis in patients with familial adenomatous polyposis: functional outcome and neoplasia control. *Dis Colon Rectum*. 2001;44:1590-1596.
- Ooi BS, Remzi FH, Gramlich T, Church JM, Preen M, Fazio VW. Anal transitional zone cancer after restorative proctocolectomy and ileoanal anastomosis in familial adenomatous polyposis: report of two cases. *Dis Colon Rectum*. 2003;46:1418-1423.
- Jones IT, Fazio VW, Weakly FL, Jagelman DG, Lavery IC, McGannon E. Desmoid tumors in familial polyposis coli. *Ann Surg*. 1986;204:94-97.
- Heiskanen I, Jarvinen HJ. Occurrence of desmoid tumors in familial adenomatous polyposis and results of treatment. *Int J Colorectal Dis*. 1996;11:157-162.
- Lynch H, Fitzgibbons R. Surgery, desmoid tumors, and familial adenomatous polyposis: case report and literature review. *Am J Gastroenterol*. 1996;91:2598-2601.
- Soravia C, Berk T, McLeod RS, Cohen Z. Desmoid disease in patients with familial adenomatous polyposis. *Dis Colon Rectum*. 2000;43:363-369.
- Steinbach G, Lynch PM, Phillips RKS, et al. The effect of celecoxib, a cyclooxygenase-2 inhibitor in familial adenomatous polyposis. *N Engl J Med*. 2000;342:1946-1952.
- Tonelli F, Valanzano R, Messerini L, Ficari F. Long-term treatment with sulindac in familial adenomatous polyposis: is there an actual efficacy in prevention of rectal cancer? *J Surg Oncol*. 2000;74:15-20.
- Lynch HT, De La Chapelle A. Hereditary colorectal cancer. *N Engl J Med*. 2003;348:919-932.
- Tsukada K, Church JM, Jagelman DG, et al. Noncytotoxic drug therapy for intra-abdominal desmoid tumor in patients with familial adenomatous polyposis. *Dis Colon Rectum*. 1992;35:29-33.
- Sagar PM, Moslein G, Dozois RR. Management of desmoid tumors in patients after ileal pouch-anal anastomosis for familial adenomatous polyposis. *Dis Colon Rectum*. 1998;41:1350-1356.

The genetics of FAP can be a nightmare.¹

An enduring concern in the treatment of FAP is the course of the disease after colectomy; its rarity and its clinical heterogeneity limit our understanding of extracolonic neoplastic manifestations, especially if these develop at a relatively advanced age. Tulchinsky et al report their experience with several extraintestinal complications of FAP; they have also highlighted several factors that influence their choice of prophylactic surgery, including the risk of rectal tumor development and desmoid tumors. Further comment is merited about the correlation between the phenotype: the clinical behavior of FAP, and the mutation in the adenomatous polyposis coli (*APC*) gene on chromosome 5q21; such a mutation is detectable in about 80% of the patients with FAP. Although its testing is increasingly more accessible, there is a compelling need for genetic counseling.²

The molecular pathophysiology of phenotype-genotype correlations in FAP is poorly understood but seems to stem from the specific protein domain inactivation associated with different mutations within this gene. Other exogenous and endogenous factors, including modifier genes, contribute to the clinical heterogeneity of FAP.³

Our experience indicates a greater risk of dysplastic gastric fundic gland polyps and duodenal adenomata in pediatric patients with *APC* mutations between codons 1225 and 1694.⁴ The risk of rectal stump cancer complicating IRA has been similarly characterized; Wu et al⁵ described severe polyposis in patients harboring *APC* mutations at codons 1309 or 1328. They stressed that the prognosis for retaining the colon in these patients is poor. Bertario et al⁶ addressed the question of rectal stump cancer in patients with FAP treated with IRA vis-à-vis *APC* mutations; they described a significantly greater rectal polyp burden and higher rectal stump cancer risk in patients harboring mutations between codons 1250 and 1464 compared with individuals with mutations upstream or downstream of this segment of the *APC* gene. The same group has further characterized a markedly increased risk of developing desmoid disease in patients with FAP harboring *APC* mutations upstream of codon 1444 (odds ratio, 11.6 ≤ codon 1444 compared with >codon 1444).⁶

Future studies will have to address the effect of a more comprehensive approach to treatment of FAP, including *APC* and human homolog of mutY (*MYH*) gene mutation analysis, to anticipate the course of the disease. Novel techniques in improving survival include laparoscopic surgery for colectomy, and the effect of chemopreventive agents.

Thomas Attard, MD
Henry Lynch, MD

Correspondence: Dr Lynch, Department of Preventive Medicine, Creighton University School of Medicine, 2500 California Plaza, Omaha, NE 68178 (ytlynch@creighton.edu).

1. Lynch HT, Smyrk TC. Classification of familial adenomatous polyposis: a diagnostic nightmare. *Am J Hum Genet.* 1998;62:1288-1289.
2. Giardiello FM, Brensinger JD, Petersen GM, et al. The use and interpretation of commercial *APC* gene testing for familial adenomatous polyposis. *N Engl J Med.* 1997;336:823-827.
3. Crabtree MD, Tomlinson IP, Hodgson SV, Neale K, Phillips RK, Houlston RS. Explaining variation in familial adenomatous polyposis: relationship between genotype and phenotype and evidence for modifier genes. *Gut.* 2002;51:420-423.
4. Attard TM, Cuffari C, Tajouri T, et al. Multicenter experience with upper gastrointestinal polyps in pediatric patients with familial adenomatous polyposis. *Am J Gastroenterol.* 2004;99:681-686.
5. Wu JS, Paul P, McGannon EA, Church JM. *APC* genotype, polyp number, and surgical options in familial adenomatous polyposis. *Ann Surg.* 1998;227:57-62.
6. Bertario L, Russo A, Radice P, et al. Genotype and phenotype factors as determinants for rectal stump cancer in patients with familial adenomatous polyposis: Hereditary Colorectal Tumors Registry. *Ann Surg.* 2000;231:538-543.