

Treatment of Stage IVA Hepatocellular Carcinoma

Should We Reappraise the Role of Surgery?

Mircea Chirica, MD; Olivier Scatton, MD; Pierre-Philippe Massault, MD; Thomas Aloia, MD; Bruto Randone, MD; Bertrand Dousset, MD; Paul Legmann, MD; Olivier Soubrane, MD

Hypothesis: A subset of patients with stage IVA hepatocellular carcinoma (HCC) and preserved liver function may benefit from hepatic resection.

Design: Retrospective review of a prospectively collected database.

Setting: An academic tertiary care hepatobiliary unit.

Patients: Twenty patients who underwent surgical treatment for stage IVA HCC between July 1998 and October 2004 were identified from the database.

Intervention: Intraoperative ablation of HCC nodules was combined with resection in 6 patients (30%) to increase resectability. Three patients also underwent resection of extrahepatic tumors. Five patients (25%) had macroscopic invasion of the portal vein and 2 patients (10%) underwent thrombectomy of the vena cava.

Main Outcome Measures: Intraoperative data, recurrence, and long-term survival rates were analyzed.

Results: Postoperative mortality and morbidity were 5% and 30%, respectively. The median number of resected tumors per patient was 3, and the median diameter of the largest tumor was 60 mm. With a median follow-up of 23 months, 14 patients (70%) developed recurrence. Treatment of recurrence was possible in 10 patients and included transarterial chemoembolization in 7 patients (35%), of whom 2 (10%) had radiofrequency ablation first, and systemic chemotherapy in 3 patients (15%). Median survival time was 32 months, and the actuarial 1-, 3-, and 5-year survival rates were 73%, 56%, and 45%, respectively.

Conclusions: Long-term survival can be achieved using an aggressive surgical approach in select patients with advanced HCC. Patients with stage IVA HCC should be followed up by a multidisciplinary team because recurrence is common and sequential treatments may prolong survival.

Arch Surg. 2008;143(6):538-543

FOR PATIENTS WITH SMALL hepatocellular carcinoma (HCC), liver transplantation (LT) and hepatic resection can achieve cure. However, curative surgery is feasible for less than 30% of patients either because of locally advanced disease or the presence of distant metastases at the time of diagnosis.¹ When patients are found to

proach, and the role of surgery for these patients remains undefined.⁴⁻⁷ Several surgical treatment options are available for patients with advanced HCC and preserved liver function (Child-Pugh class A), including radiofrequency ablation (RFA), cryotherapy, ethanol injection, transarterial chemoembolization (TACE), and surgical resection. While RFA is frequently used in combination with surgery to increase resectability rates in patients with colorectal metastases,^{8,9} multimodal surgical treatments are seldom used for the treatment of patients with HCC.

The main factors that restrict the indications for surgery in patients with advanced HCC are the extent of tumoral involvement of the liver, the degree of underlying liver disease, and the size of the liver remnant. However, patients who are candidates for surgery appear to have a survival benefit, with 20% to 40% postresection 5-year survival rates reported after resection of bilobar HCC.^{3,10-12} Similarly, survival following resection of HCC in patients with

See Invited Critique at end of article

have distant metastases, the disease is classified as stage IVB according to the International Union Against Cancer TNM system² (**Table 1**), and palliative treatments are the only reasonable option.³

For patients with stage IVA HCC (multiple bilobar tumors, tumoral invasion of the portal vein, or invasion of adjacent organs), there is no standard therapeutic ap-

Author Affiliations:

Departments of Hepatobiliary Surgery and Transplantation (Drs Chirica, Scatton, Massault, Randone, Dousset, and Soubrane) and Radiology (Dr Legmann), Hôpital Cochin, Assistance Publique-Hôpitaux de Paris, Université Paris Descartes, Paris, France; and Department of Surgery, Division of Abdominal Transplantation and Hepatobiliary Surgery, Baylor College of Medicine, Houston, Texas (Dr Aloia).

Table 1. UICC TNM Classification for Hepatocellular Carcinoma

Classification	Description
T factor	
T1	Solitary, ≤ 2 cm, no vascular invasion
T2	Solitary, ≤ 2 cm, vascular invasion
T3	Multiple/unilobar, ≤ 2 cm, no vascular invasion
	Solitary, > 2 cm, no vascular invasion
	Solitary, > 2 cm, vascular invasion
T4	Multiple/unilobar, ≤ 2 cm, vascular invasion
	Multiple/unilobar, > 2 cm, irrespective of vascular invasion
	Multiple/bilobar
Stage	Invasion of major portal or hepatic vein branch
	Invasion of adjacent organs
	Perforation of visceral peritoneum
I	T1N0M0
II	T2N0M0
IIIA	T3N0M0
IIIB	T1-3N1M0
IVA	T4N0/1M0
IVB	Any T/NM1

Abbreviation: UICC, International Union Against Cancer.

portal vein invasion compares favorably with the survival rates reported after nonoperative treatment.^{3,13-15}

Percutaneous ablative techniques (RFA, ethanol injection) are seldom used alone to treat stage IVA HCC because they are limited by the number, size, and location of the tumoral nodules.¹⁶ Nevertheless, their intraoperative use as a complement to surgery may achieve complete destruction of otherwise unresectable HCC. These techniques can also be successfully used for the treatment of recurrence.

Given these data, we have treated a number of patients with advanced-stage HCC with surgery, including initial hepatic resection combined with local destruction of unresectable nodules, followed by an aggressive combined-modality treatment of recurrent disease. The aim of this study was to evaluate the impact of this approach for select patients with stage IVA HCC.

METHODS

Between January 1998 and July 2004, 128 patients underwent liver resection for HCC in our unit. Twenty of these patients (16%) had stage IVA disease according to the International Union Against Cancer TNM classification and formed the cohort of this study. Prior to hepatic resection, each patient provided a medical history and underwent physical examination, screening for hepatitis B and hepatitis C, serum laboratory tests assessing liver function, hemostasis, and renal function and determination of serum α -fetoprotein level (α FP). Abdominal computed tomography (CT) and/or magnetic resonance imaging were used to assess local tumor extension, and thoracic CT was systematically performed to detect the presence of pulmonary metastases.

All patients presenting with HCC within the Milan criteria (single nodule < 5 cm, < 3 nodules < 3 cm, and no vascular invasion) are considered for LT in our institution.¹⁷ According to our policies, partial liver resection prior to LT may be indicated in some of these patients as a bridge to transplanta-

Table 2. Characteristics of the Patients Selected for an Aggressive Surgical Treatment

Characteristic	No. (%)
Men	19
Women	1
Age, y, mean (SD)	58 (13)
Child-Pugh class A	20 (100)
Etiology	
Hepatitis B	6 (30)
Hepatitis C	6 (30)
Alcohol	8 (40)
Stage IV	
Unilobar	3
Bilobar	17
Portal vein invasion	5 (25)
Hepatic vein/vena cava invasion	2 (10)
Adjacent organs invasion	3 (15)

tion and/or for selection before LT on the basis of histopathologic criteria but not as a tumor downstaging strategy. However, no patient in this series was eligible for LT since tumor characteristics did not meet the Milan criteria in all cases. Advanced HCC in the setting of severe cirrhosis (Child-Pugh classes B and C) was considered a contraindication for surgery and patients were offered alternative treatments.

In patients with technically resectable (tumor was deemed completely resectable with a residual functional liver parenchyma of at least 30%) stage IVA HCC and preserved liver function and without evidence of portal hypertension, an aggressive therapeutic strategy was considered after discussion in a multidisciplinary conference. Unilateral thrombosis of the portal vein or partial invasion of the vena cava were not considered contraindications to surgery. Intraoperative RFA was coupled with resection whenever necessary to obtain a complete tumoral treatment. Transarterial chemoembolization was not performed preoperatively.

Primary end points were overall and disease-free survival. Preoperative characteristics of patients with stage IVA HCC who underwent liver resection are presented in **Table 2**. There were 19 men and 1 woman with a mean (SD) age of 58 (13) years. Underlying liver disease, which was present in all patients, was due to viral hepatitis in 12 patients (60%) and alcohol in 8 patients (40%). Values of serum α FP were in excess of 400 ng/mL (to convert to micrograms per liter, multiply by 1) in 10 patients (50%). All intraoperative and postoperative complications were recorded. Operative mortality was defined as patient death during in-hospital stay.

Postoperative follow-up, including clinical examination, measure of serum levels of α FP, and liver ultrasonography or CT scan, was conducted every 4 months during the first postoperative year and every 6 months thereafter. Liver CT and/or magnetic resonance imaging were performed when tumor recurrence was suspected. In the presence of resectable recurrence, patients were considered for further hepatic resection. Patients with small unresectable recurrence were treated with RFA and/or TACE while patients with more than 3 nodules more than 5 cm were treated with TACE alone. Patients with more extensive recurrence (portal vein thrombosis, distant metastases) were treated with systemic chemotherapy according to protocol.

For statistical analysis, quantitative variables were compared using the Mann-Whitney *U* test. Qualitative variables were analyzed using the χ^2 test or Fisher exact test when necessary. Data were expressed as mean (SD) or as median and range. Differences at $P < .05$ were considered significant.

Table 3. Surgical Procedures Performed in Patients With Stage IVA Hepatocellular Carcinoma

Surgical Treatment	No. (%)
Major hepatectomy	7 (35)
Right hepatectomy (segments 5-8)	3
Right trisectionectomy (segments 4-8)	2
Left hepatectomy	1
Central hepatectomy (segments 4, 5, and 8)	1
Intraoperative RFA	6 (30)
Resection of adjacent organs	3 (15)
IVC thrombectomy	2 (10)

Abbreviations: IVC, inferior vena cava; RFA, radiofrequency ablation.

RESULTS

OPERATIVE MANAGEMENT

Seventeen patients (85%) had bilobar tumors and 5 patients (25%) had unilateral tumoral thrombus in the portal vein, of whom 2 (10%) had associated inferior vena cava invasion. The portal vein thrombi were limited to the segmental branches (2 patients) or the isolateral portal trunk (3 patients) and did not require resection and/or reconstruction of the main portal vein. Seven patients (35%) underwent a major hepatectomy (resection of >3 segments). Preoperative portal vein embolization (PVE) was used in 1 patient in whom the left liver represented 28% of standard liver volume. Four weeks later, his left liver volume had increased to 35% and he underwent right hepatectomy as well as wedge resection of a segment 2 tumor.

At the time of resection, 6 patients were treated with RFA for a median of 1 nodule (range, 1-3 nodules). All of these patients underwent major liver resection (>3 segments) for bilobar HCC, and resection of remaining nodules would have led to insufficient (<30%) residual liver parenchyma. Thrombectomy of the inferior vena cava under complete vascular exclusion of the liver for a period of 45 minutes was associated with right trisectionectomy in 2 patients. Invasion of adjacent organs was present in 3 patients (15%). Two of them underwent partial resection of the diaphragm while resection of an invaded right adrenal gland was performed in 1 patient (**Table 3**).

CASE EXAMPLE

A 40-year-old African patient with a history of chronic hepatitis B virus was referred to our institution because of a primary liver tumor. Computed tomographic scan showed a large HCC in the left liver, with tumoral thrombosis of the left portal vein (**Figure 1A**) and a 1.5-cm nodule in segment 6 (**Figure 1B**). Serum α FP level was 17 000 ng/mL. He underwent left hepatectomy (resection of segments 2, 3, and 4, according to Couinaud classification), thrombectomy of the portal vein, and RFA of the tumor in the right lobe. Histopathologic examination revealed a poorly differentiated HCC, with tumoral thrombus in the left portal vein. The nontumoral liver exhibited severe fibrosis (A1F3).

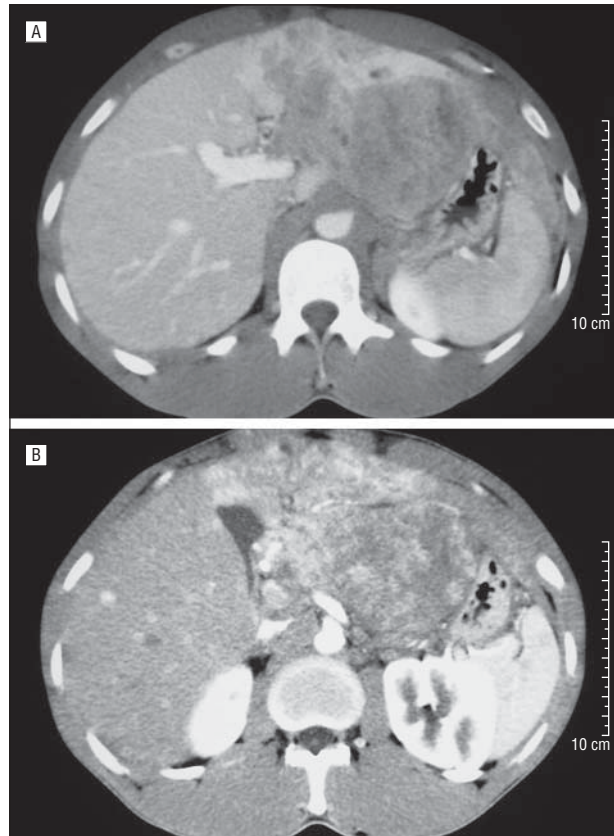


Figure 1. Large hepatocellular carcinoma of the left liver associated with tumoral thrombus in the left portal vein (A) and second tumor in segment 6 (B).

Two patients (10%) underwent laparoscopic resection. This technique was chosen in 2 patients during the last period of the study considering our increasing experience with laparoscopic hepatic resection. The first patient was a 43-year-old man with bilobar HCC including a 7-cm tumor located in segment 3 and a 2-cm peripheral tumor in segment 6. A laparoscopic left lateral sectionectomy and a wedge resection of the segment 6 tumor were performed. The second patient was a 51-year-old man with single peripheral 7-cm HCC of segment 6, with invasion of the pre renal fascia and right adrenal gland. He underwent laparoscopic segmentectomy 6 and right adrenalectomy.

Intraoperative transfusion was required in 9 patients (45%). The Pringle maneuver was used in 10 patients (50%), and mean (SD) duration of hepatic clamping was 23 (28) minutes. Mean (SD) operative time was 290 (144) minutes.

TUMORAL FEATURES

The median number of tumors resected per patient was 3 (range, 1-7) and the median diameter of resected tumors was 60 mm (range, 25-150 mm). Presence of microscopic vascular embolus and satellitosis was documented in 11 patients (55%) and 7 patients (35%), respectively. Twelve patients (60%) had cirrhosis of the nontumoral liver (F4), while 8 patients (40%) had severe fibrosis (F3). All patients underwent R0 resection.

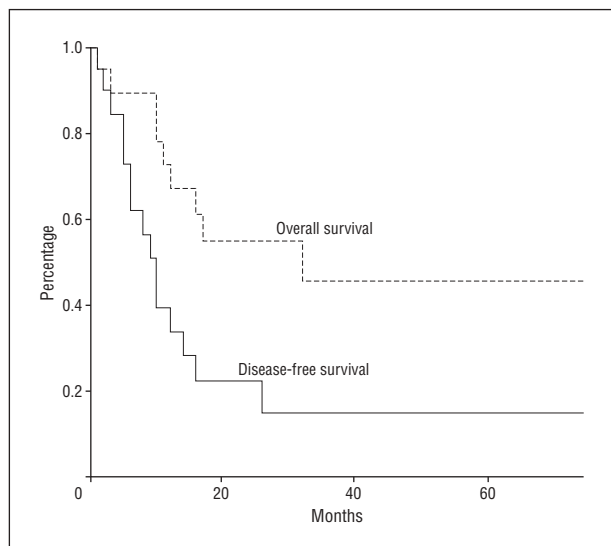


Figure 2. Kaplan-Meier overall and disease-free survival curves following aggressive treatment of advanced hepatocellular carcinoma.

POSTOPERATIVE OUTCOME

One patient (5%) died on postoperative day 22 of sepsis and multiorgan failure. The overall morbidity was 30%, with the most frequent complications being postoperative ascites (20%) and pulmonary complications (15%). Median intensive care unit stay was 5 days (range, 0-35 days) and median in-hospital stay was 16 days (range, 7-210 days).

RECURRENCE AND SURVIVAL

The median follow-up interval was 23 months. Overall survival rates at 1, 3, and 5 years were 73%, 56%, and 45%, respectively. Disease-free survival rates at 1, 3, and 5 years were 40%, 20%, and 17%, respectively (**Figure 2**).

At last follow-up, 14 patients (70%) had tumor recurrence. The median delay between hepatic resection and recurrence was 10 months (range, 2-75 months). Eight patients had intrahepatic recurrence only, while 6 patients had concomitant intrahepatic and extrahepatic recurrence (lung, $n=5$; peritoneal carcinomatosis, $n=1$). None of the patients with recurrence were eligible for a second liver resection because of the multifocal pattern of recurrence within the liver, portal vein thrombosis, or the presence of extrahepatic disease. Treatment of recurrence was undertaken in 10 patients (71%). Seven patients underwent TACE, with a median of 3 treatments per patient (range, 1-5), and 2 of them also had percutaneous RFA of recurrent nodules. Three patients whose liver reserves would not allow for TACE or RFA were treated with systemic chemotherapy according to protocol. Patients treated by TACE showed a better outcome (median survival from the moment of recurrence, 23 months) than patients treated with systemic chemotherapy (median survival, 6 months) (**Table 4**).

COMMENT

Identification of the optimal therapeutic approach to patients with advanced HCC represents a difficult chal-

Table 4. Pattern of Recurrence and Treatment of Recurrent Tumors Following Resection of Stage IVA Hepatocellular Carcinoma

	No. (%)
Recurrence	14 (70)
Site of recurrence	
Intrahepatic	14 (100)
Lung	6 (43)
Peritoneum	1 (7)
Treatment of recurrence	10 (71)
TACE	7 (50)
RFA	2 (14)
Chemotherapy	3 (15)

Abbreviations: RFA, radiofrequency ablation; TACE, transarterial chemoembolization.

lenge. In general, the prognosis of these patients is dismal. Results of liver resection for advanced HCC have been initially disappointing because of high recurrence rates and low survival rates.¹⁸ The presence of portal vein thrombosis is an ominous finding and the development of HCC in the setting of cirrhosis in 80% of patients further limits the feasibility of hepatic resection.³ Liver transplantation in patients with advanced HCC has not met expectations, and the results cannot justify the inscription of these patients on transplant waiting lists.^{17,19,20}

However, recent reports from specialized centers point out that an aggressive surgical approach may improve survival rates for patients with HCC, even in the presence of poor prognostic factors, such as portal vein thrombosis or bilobar disease.¹⁰⁻¹⁵ New therapeutic strategies have been developed in an effort to improve the survival of patients with stage IVA HCC. Ku et al¹ used a percutaneous isolated hepatic perfusion technique in association with reductive surgery for the treatment of 25 patients with advanced HCC. Their excellent 42% five-year overall survival rate suggests the need for further investigations in this direction. Lau et al^{21,22} performed extensive resections and even debulking surgery following downstaging of advanced HCC by systemic chemotherapy and reported a 5-year survival rate of 57%.

Based on these encouraging results we have also applied an aggressive surgical strategy, with combined resection and ablative therapies, to some highly select patients presenting with stage IVA HCC. Intraoperative RFA was used to increase resectability in one-third of patients.

The first finding of this study was a high overall survival rate, reaching 45% at 5 years. The combined treatment with resection and RFA allowed extension of the indications for surgery in patients with advanced HCC without an appreciable deficit in survival. In a recent randomized trial, Chen et al²³ showed no difference in the outcome of patients with small HCC treated by either percutaneous RFA or liver resection. A recent meta-analysis evaluating the efficacy of tumoral destruction by RFA concluded that better tumoral control was achieved when RFA was performed intraoperatively compared with percutaneous RFA.²⁴ In view of these data, we think that intraoperative use of RFA may increase resectability of patients with otherwise unresectable advanced HCC. Pre-

operative PVE allowed us to perform a major hepatic resection with curative intent in a patient with an otherwise unresectable HCC. As previously reported, PVE may increase tumor resectability²⁵ because of the hypertrophy of the future remnant liver and may diminish postoperative morbidity in patients with cirrhosis undergoing major liver resection.²⁶ Therefore, PVE should be considered in select patients with cirrhosis who are candidates for major liver resection for stage IVA HCC.

We report a 5-year disease-free survival rate of 17% in 20 patients, of whom 5 had macroscopic invasion of the portal vein and 2 had invasion of the inferior vena cava. Theoretically, the best treatment for recurrent HCC is liver resection.²⁷ None of our patients had resectable disease at the time of recurrence because of the multifocal pattern within the liver or extrahepatic localization of tumoral nodules. Several reports have pointed out that intrahepatic metastasis of HCC arises via the portal veins and that anatomical segment-oriented resections that include the entire portal drainage territory provide less recurrence and better survival rates than wedge resections.^{28,29} The frequent finding of an important tumoral burden arising in a cirrhotic liver did not allow us to make anatomical resections in every patient; the use of wedge resections and local destructive therapies may explain the high recurrence rate in our patients.

The prolonged survival despite a high recurrence rate could be explained by the aggressive treatment of recurrence by percutaneous RFA and TACE. Chemoembolization has been shown to increase survival in patients with unresectable HCC³⁰⁻³² and thus is likely to improve the survival of patients with unresectable recurrence after resection. In our study, patients who were treated by TACE at the time of recurrence showed a better outcome. This result may be explained by the fact that TACE was offered only to the patients who were most fit.

The second main finding was a low operative risk. The 5% mortality and 30% morbidity rates are comparable with those reported by most of the recent series following major liver resection.^{6,12,15,22} This fact is probably due to careful patient selection, as we use this strategy only for patients with Child-Pugh class A disease in the absence of other major comorbidities. Using techniques such as complete vascular exclusion, nodules situated near major vascular structures can be safely destroyed. Furthermore, destruction by RFA of HCC nodules allows sparing of liver parenchyma, possibly diminishing postoperative morbidity and mortality in patients with cirrhosis. Our results stress the need to better define in the future resectability criteria for advanced HCC.

This study can be criticized on the following aspects: (1) It is a retrospective study comprising a small number of patients. This fact demonstrates that this is a highly select population and that only a small percentage of patients with advanced HCC could benefit from such an aggressive strategy; it also predicts the difficulties of performing a randomized controlled study on this topic. (2) The patients in this study were a heterogeneous group. However, this reflects the limitation of the current staging system, which places in the same group (stage IVA) patients who may have different prognoses (portal vein invasion vs bilobar).

CONCLUSIONS

On the basis of the results of our study, we conclude that highly select patients with stage IVA HCC and preserved liver function should be considered for surgical treatment. In some cases, the addition of local destructive therapies may increase resectability rates. Chemoembolization as well as chemotherapy protocols should be reserved for the treatment of unresectable recurrence. The use of this therapeutic strategy may prolong survival for patients with advanced HCC.

Accepted for Publication: January 10, 2007.

Correspondence: Prof Olivier Soubrane, Department of Hepatobiliary Surgery and Transplantation, Hôpital Cochin, 27 Rue du Faubourg St Jacques, 75014 Paris, France (olivier.soubrane@cch.aphp.fr).

Author Contributions: *Study concept and design:* Chirica, Scatton, Dousset, and Soubrane. *Acquisition of data:* Chirica, Scatton, Massault, Randone, and Legmann. *Analysis and interpretation of data:* Chirica, Scatton, Aloia, and Soubrane. *Drafting of the manuscript:* Chirica, Scatton, Aloia, Randone, Dousset, Legmann and Soubrane. *Critical revision of the manuscript for important intellectual content:* Chirica, Scatton, Massault, Aloia, and Soubrane. *Statistical analysis:* Aloia and Soubrane. *Administrative, technical, and material support:* Scatton, Massault, and Aloia. *Study supervision:* Soubrane.

Financial Disclosure: None reported.

REFERENCES

1. Ku Y, Iwasaki T, Tominaga M, et al. Reductive surgery plus percutaneous isolated hepatic perfusion for multiple advanced hepatocellular carcinoma. *Ann Surg.* 2004;239(1):53-60.
2. Sobin LH, Whitekind Ch, eds. *TNM Classification of Malignant Tumours.* 5th ed. New York, NY: John Wiley; 1997.
3. Poon RT, Fan ST, Ng IO, et al. Prognosis after hepatic resection for stage IVA hepatocellular carcinoma: a need for reclassification. *Ann Surg.* 2003;237(3):376-383.
4. Wayne JD, Lauwers GY, Ikai I, et al. Preoperative predictors of survival after resection of small hepatocellular carcinomas. *Ann Surg.* 2002;235(5):722-730.
5. Wu FS, Zhao WH, Liang TB, et al. Survival factors after resection of small hepatocellular carcinoma. *Hepatobiliary Pancreat Dis Int.* 2005;4(3):379-384.
6. Poon RT, Fan ST, Lo CM, Liu CL, Wong J. Long-term survival and pattern of recurrence after resection of small hepatocellular carcinoma in patients with preserved liver function: implications for a strategy of salvage transplantation. *Ann Surg.* 2002;235(3):373-382.
7. Ikai I, Arai S, Kojiro M, et al. Reevaluation of prognostic factors for survival after liver resection in patients with hepatocellular carcinoma in a Japanese nationwide survey. *Cancer.* 2004;101(4):796-802.
8. Pawlik TM, Izzo F, Cohen DS, Morris JS, Curley SA. Combined resection and radiofrequency ablation for advanced hepatic malignancies: results in 172 patients. *Ann Surg Oncol.* 2003;10(9):1059-1069.
9. Abdalla EK, Vauthey JN, Ellis LM, et al. Recurrence and outcomes following hepatic resection, radiofrequency ablation, and combined resection/ablation for colorectal liver metastases. *Ann Surg.* 2004;239(6):818-825.
10. Liu CL, Fan ST, Lo CM, Ng IO, Poon RT, Wong J. Hepatic resection for bilobar hepatocellular carcinoma: is it justified? *Arch Surg.* 2003;138(1):100-104.
11. Ng KK, Vauthey JN, Pawlik TM, et al. Is hepatic resection for large or multinodular hepatocellular carcinoma justified? Results from a multi-institutional database. *Ann Surg Oncol.* 2005;12(5):364-373.
12. Wu CC, Ho WL, Lin MC, et al. Hepatic resection for bilobar multicentric hepatocellular carcinoma: is it justified? *Surgery.* 1998;123(3):270-277.
13. Wu CC, Hsieh SR, Chen JT, et al. An appraisal of liver and portal vein resection for hepatocellular carcinoma with tumor thrombi extending to portal bifurcation. *Arch Surg.* 2000;135(11):1273-1279.
14. Ohkubo T, Yamamoto J, Sugawara Y, et al. Surgical results for hepatocellular carcinoma with macroscopic portal vein tumor thrombosis. *J Am Coll Surg.* 2000;191(6):657-660.
15. Pawlik TM, Poon RT, Abdalla EK, et al. Hepatectomy for hepatocellular carcinoma with major portal or hepatic vein invasion: results of a multicenter study. *Surgery.* 2005;137(4):403-410.

16. Poon RT, Fan ST, Tsang FH, Wong J. Locoregional therapies for hepatocellular carcinoma: a critical review from the surgeon's perspective. *Ann Surg.* 2002; 235(4):466-486.
17. Mazzaferro V, Regalia E, Doci R, et al. Liver transplantation for the treatment of small hepatocellular carcinomas in patients with cirrhosis. *N Engl J Med.* 1996; 334(11):693-699.
18. Shimada M, Takenaka K, Kawahara N, et al. Surgical treatment strategy for patients with stage IV hepatocellular carcinoma. *Surgery.* 1996;119(5): 517-522.
19. Bismuth H, Majno PE, Adam R. Liver transplantation for hepatocellular carcinoma. *Semin Liver Dis.* 1999;19(3):311-322.
20. Klintmalm GB. Liver transplantation for hepatocellular carcinoma: a registry report of the impact of tumor characteristics on outcome. *Ann Surg.* 1998;228 (4):479-490.
21. Lau WY, Leung TW, Lai BS, et al. Preoperative systemic chemoimmunotherapy and sequential resection for unresectable hepatocellular carcinoma. *Ann Surg.* 2001;233(2):236-241.
22. Lau WY, Ho SK, Yu SC, Lai EC, Liew CT, Leung TW. Salvage surgery following downstaging of unresectable hepatocellular carcinoma. *Ann Surg.* 2004;240 (2):299-305.
23. Chen MS, Li JQ, Zheng Y, et al. A prospective randomized trial comparing percutaneous local ablative therapy and partial hepatectomy for small hepatocellular carcinoma. *Ann Surg.* 2006;243(3):321-328.
24. Sutherland LM, Williams JA, Padbury RT, Gotley DC, Stokes B, Maddern GJ. Radiofrequency ablation of liver tumors: a systematic review. *Arch Surg.* 2006; 141(2):181-190.
25. Imamura H, Shimada R, Kubota M, et al. Preoperative portal vein embolization: an audit of 84 patients. *Hepatology.* 1999;29(4):1099-1105.
26. Farges O, Belghiti J, Kianmanesh R, et al. Portal vein embolization before right hepatectomy: prospective clinical trial. *Ann Surg.* 2003;237(2):208-217.
27. Minagawa M, Makuuchi M, Takayama T, Kokudo N. Selection criteria for repeat hepatectomy in patients with recurrent hepatocellular carcinoma. *Ann Surg.* 2003; 238(5):703-710.
28. Imamura H, Matsuyama Y, Tanaka E, et al. Risk factors contributing to early and late phase intrahepatic recurrence of hepatocellular carcinoma after hepatectomy. *J Hepatol.* 2003;38(2):200-207.
29. Regimbeau JM, Kianmanesh R, Farges O, Dondero F, Sauvanet A, Belghiti J. Extent of liver resection influences the outcome in patients with cirrhosis and small hepatocellular carcinoma. *Surgery.* 2002;131(3):311-317.
30. Llovet JM, Real MI, Montana X, et al. Arterial embolisation or chemoembolisation versus symptomatic treatment in patients with unresectable hepatocellular carcinoma: a randomised controlled trial. *Lancet.* 2002;359(9319):1734-1739.
31. Lo CM, Ngan H, Tso WK, et al. Randomized controlled trial of transarterial lipiodol chemoembolization for unresectable hepatocellular carcinoma. *Hepatology.* 2002;35(5):1164-1171.
32. Llovet JM, Bruix J. Systematic review of randomized trials for unresectable hepatocellular carcinoma: Chemoembolization improves survival. *Hepatology.* 2003; 37(2):429-442.

INVITED CRITIQUE

The report by Chirica et al retrospectively analyzes the outcomes of 20 patients who underwent surgical resection of stage IVA HCC, representing 16% of the 128 patients overall who underwent surgical treatment of HCC at this center. These patients had advanced-stage disease with a median number of 3 resected tumors per patient and a median diameter of the largest tumor of 6 cm. Five patients had major portal venous involvement and 2 had associated inferior vena cava invasion that required operative reconstruction. All patients had at least severe fibrosis in the nontumor-bearing liver with 60% having biopsy-proven cirrhosis. Impressively, Chirica et al report an operative mortality rate of only 5% with a 30% morbidity rate in this group of high-risk, advanced-stage tumors.

While this report has several limitations, including the highly select, relatively small patient cohort, it nevertheless is important in demonstrating that operative resection can be safely performed with good, long-term outcomes in a patient group that otherwise would not be considered for surgical resection at many liver centers.

However, I do not agree with the authors' claim that "Liver transplantation in patients with advanced HCC has not met expectations, and the results cannot justify the inscription of these patients on transplant waiting lists." As pointed out in the Chirica et al article, the UICC staging system classifies any patient with bilobar HCC as having T4, stage IVA disease (Table 1). While patients with major portal venous or hepatic venous tumor invasion clearly have worsened long-term results with orthotopic liver transplant, the same cannot be said for patients with small bilobar tumors (and no vascular invasion) meeting the American liver tumor study group modified American Joint Committee on Cancer stage II criteria (ie, Milan criteria),¹ currently used by the United

Network for Organ Sharing as a basis for granting exception points for organ allocation. In addition, we^{2,3} and others⁴ have demonstrated that even more patients with advanced-stage tumor (stage III United Network for Organ Sharing, American Joint Committee on Cancer, or those meeting the University of California, San Francisco criteria⁴) may undergo successful liver transplant with excellent long-term results. In this regard, patients with UICC stage IVA should undergo an individualized assessment for consideration of liver transplant. While the overall 5-year survival results of 45% in the Chirica et al report appear favorable, almost all patients in this series had tumor recurrence with a very poor 5-year disease-free survival rate of only 17%, substantially worse than for carefully selected patients who are able to undergo a transplant.

William C. Chapman, MD

Correspondence: Dr Chapman, Department of Hepatobiliary and Liver Transplantation, Washington University School of Medicine, 660 S Euclid, Campus Box 8109, St Louis, MO 63110 (chapmanw@msnotes.wustl.edu)
Financial Disclosure: None reported.

1. Mazzaferro V, Regalia E, Doci R, et al. Liver transplantation for the treatment of small hepatocellular carcinomas in patients with cirrhosis. *N Engl J Med.* 1996;334(11):693-699.
2. Goodman J, Glasgow SC, Schnitzler M, et al. Liver transplantation for hepatocellular carcinoma: expanding special priority to include stage III disease. *Arch Surg.* 2005;140(5):459-464.
3. Bharat A, Brown D, Crippin JS, et al. Pre-liver transplantation locoregional adjuvant therapy for hepatocellular carcinoma as a strategy to improve long-term survival. *J Am Coll Surg.* 2006;203(4):411-420.
4. Yao FY, Ferrell L, Bass NM, et al. Liver transplantation for hepatocellular carcinoma: expansion of the tumor size limits does not adversely impact survival. *Hepatology.* 2001;33(6):1394-1403.