

Image of the Month

Daniel Kaufman, MD; Kuang H. Kang, MD; Alexander Schwartzman, MD

A 77-YEAR-OLD WOMAN WITH HYPERTENSION, diabetes mellitus, end-stage renal disease, and hypothyroidism presented with nausea, vomiting, constipation, and obstipation of 1 day's duration. Her surgical history was significant for appendectomy, open cholecystectomy, and cesarean delivery. Physical

examination revealed a moderately distended, soft, and mildly tender abdomen, and laboratory values showed mild leukocytosis. Computed tomography (CT) revealed distended loops of small bowel and gas in the mesenteric (**Figure 1**) and intrahepatic portal (**Figure 2**) veins.

What Is the Diagnosis?

- A. Benign portal venous gas
- B. Acute mesenteric ischemia
- C. Schistosomiasis
- D. Portal pyelophlebitis

Author Affiliations: Department of Surgery, State University of New York Downstate Medical Center, Brooklyn, New York. Dr Kaufman is now with the Department of Plastic and Reconstructive Surgery, Montefiore Medical Center, Albert Einstein School of Medicine, Bronx, New York.

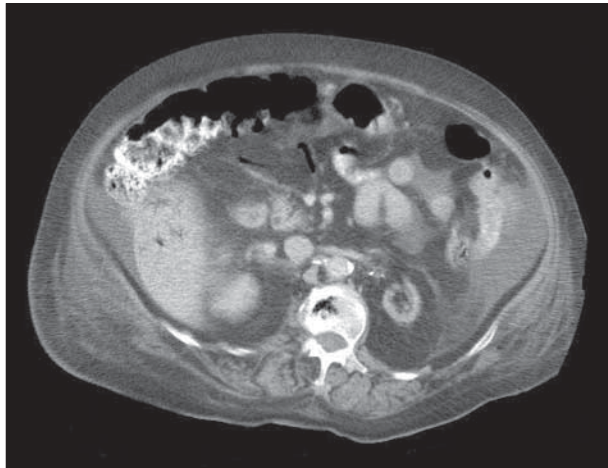


Figure 1. Abdominal computed tomography showing streaks of air in the bowel mesentery.

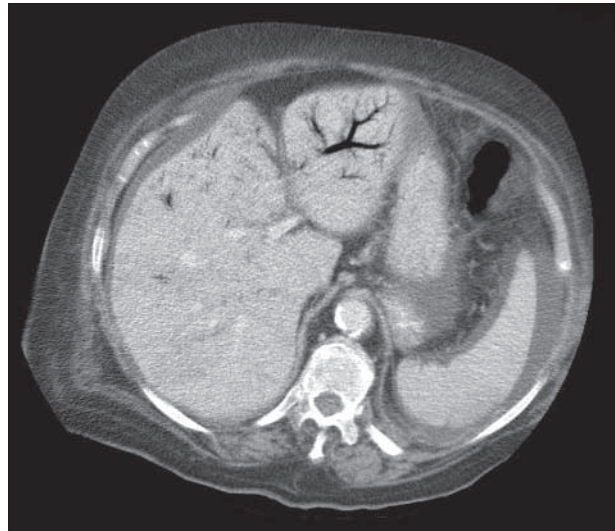


Figure 2. Abdominal computed tomography showing arborizing streaks of air in the liver.